

**Evaluation of Antiulcerogenic Activity of *Bacopa Monnieri* (LINN.) on Ethanol-Induced Gastric Injury In Mice**Rubaba Karim<sup>1</sup>, Ashfia Fatima Khan<sup>1</sup>, Sabiha Akter<sup>1</sup>, Najia Sultana Shuchi<sup>1</sup>, Mst. Maliha Tabachasum Madhuri<sup>1</sup>, Md.Nazmul Hossain<sup>1</sup><sup>1</sup>Department of Pharmacy, Primeasia University, Dhaka, Bangladesh**Correspondence Author:** Rubaba Karim, Lecturer, Department of Pharmacy, Primeasia University, Dhaka – 1213, Bangladesh**Type of Publication:** Original Research Paper**Conflicts of Interest:** Nil**Abstract**

*Bacopa monnieri* (L) is a renowned medicinal plant for its numerous therapeutic activities against a number of ailments. Bangladeshi species of *B. monnieri* has been previously reported for its anti-inflammatory activities. Therefore, the present investigation involves phytochemical screening and evaluation of antiulcerogenic activity of *B. monnieri* extracts of different solvent medium by *in-vivo* analysis. The study was conducted by using ethanol-induced gastric injury in Swiss albino mice model to evaluate anti-ulcer effect of *B. monnieri* (whole plant). Three different solvent systems (water, ethanol and carbon tetrachloride) were used to prepare plant extract. Animals were pretreated with 200mg/kg and 400mg/kg (body weight, p.o.) of the plant extracts in 0.2% tween 80 where omeprazole (20 mg/kg b.w. in 0.2% tween 80, p.o.) was used as the reference drug. The extent of gastric injury was evaluated by assessment of gross appearance of gastric areas to determine ulcer index and histology of stomach. A dose-dependent therapeutic effect against gastric ulcer was found with all three extracts of *Bacopa monnieri* where ethanolic extract of the plant showed statistically significant result (\*\* $p < 0.01$ ) when compared with ulcerogenic animal group. Furthermore, the therapeutic

effect of 400mg/kg (b.w. p.o.) of *B. monnieri* ethanolic extract exhibited close relation with pretreatment by omeprazole. The present study suggests ethanol as a suitable extraction medium for *Bacopa monnieri* (L) in order to evaluate its antiulcerogenic activity. Treatment with this extract leads to extensive protection against gastric ulcer providing a scientific basis for its traditional uses as a cure for ulcer.

**Keywords:** *Bacopa monnieri*, antiulcerogenic, ulcer, gastric injury, gastric ulcer**1. Introduction**

Crude drugs of plant origin have been employed as preventives and cure of different ailments for many years. The interest in the employment of herbal products has been growing day by day all over the world <sup>[1]</sup>. *Bacopa monnieri* Linn. (Family: Scrophulariaceae), also known as brahmi, bacopa and thyme leaved gratiola, has been regarded as one of the popular herbal remedy in Ayurveda system [2,3]. The plant is distributed abundantly in India, Nepal, Srilanka, China, Taiwan, Vietnam, Florida and also in many other warmer regions of the world [4].

Many phytochemical constituents have been isolated from this plant that include alkaloid brahmine, nicotine, herpestine, bacosides A[3-( $\alpha$ -L-arabinopyranosyl)-O- $\beta$ -Dglucopyranoside-10,20-dihydroxy-16-keto-dammar-24-

ene], triterpenoidsaponins, saponins A, B and C, betulinic acid, D-mannitol, stigmastanol,  $\beta$ -sitosterol, stigmasterol and pseudojubilogenin glycoside [5-12]. *Bacopamonnieri* extract has been reported to exhibit several pharmacological activities, for example, neuroprotective effect [13-15], an antioxidant [16-18], an antiparkinsonian agent [19], hepatoprotective agent [20], anti-depressant [21], anti-stress [22], anti-cancer [23], antimicrobial effect [24,25], endocrine effect [26,27], anti-inflammatory agent [28], gastrointestinal effect [29] and antiulcerogenic agent [30].

Gastric ulcer is considered one of the most significant gastrointestinal disorders that has become an alarming health issue all over the world. Such ulcer occurs due to a condition involving a lesion in the gastric mucosa that perforates deep into the submucosal zone of the stomach [31]. One of the major causes of this disorder is the imbalanced function of defensive (mucus secretion, cellular regeneration, prostaglandin, bicarbonate, nitric oxide) and noxious (gastric acid and pepsin secretion) factors of the gastrointestinal system [32]. This damages the mucosal barrier resulting ulcer, inflamed cells and in severe cases subepithelial hemorrhages in stomach [33,34]. However, other factors that raises the incidence of gastric ulcer involve smoking, stress, infection with *Helicobacter pylori*, excessive or prolong consumption of alcohol and prolong administration of NSAIDs [35-38]. Alcohol-induced gastric mucosal lesions is responsible for developing gastritis, gastric ulcer and sometimes gastric carcinoma [39]. Different experimental ulcer-induced animal models have been reported in the previous studies that involved ethanol and acetic acid-induced gastric injury [40]. Alcohol damages the gastric mucosal layer in the stomach, as a result, impairs mucus secretion (a defensive factor) causing gastrointestinal erosions and peptic ulcers [41-43]. This may even lead to more serious

complications, such as over bleeding or perforation [44, 45].

A number of synthetic remedies are as gastroprotective agents and hence control ulcer including antacids,  $H_2$  receptor blockers, proton pump inhibitors or antihistamines [46, 47]. However, at present, these drugs are coming across several limitations in terms of patient safety issues involving confined efficacy against gastric diseases and severe side effects [47-49]. Therefore, natural gastroprotective agents from plant origin are being significantly considered due to their collection from convenient sources, less side-effects and cost effectiveness. Various medicinal plants and crude drugs are currently gaining global attention for their pharmacological effect against gastric ulcer and other GI disorders [47, 50]. Former animal and *in vitro* studies have exhibited protective and curative effect of crude extract of *Bacopa monnieri* against gastric ulcer [51-54].

At present, there is limited literature available to support the antiulcerogenic effect of Bangladeshi species of *Bacopa monnieri* L. leaf or whole plant extract using various solvents. Therefore, the present study has been designed to come up with scientific evidence for the use of *B. monnieri*'s traditional ulcer healer by investigating the antiulcerogenic activity of different extracts of *Bacopa monnieri* (Linn.) on ethanol-induced gastric injury in Swiss Albino mice.

## 2. Materials and methods

### 2.1 Chemicals and reagents

Omeprazole (API) was obtained from the pharmaceutical industry Eskayef Bangladesh Ltd. Ethanol, carbon tetrachloride, tween 80 and all other reagent materials were purchased from Merck (Darmstadt, Germany) and were of analytical grade.

### 2.2 Plant collection and extract preparation

*Bacopa monnieri* L., fresh plants, were collected on January 2018 from Jahangirnagar University, Dhaka,

Bangladesh. The identification of the plant material was confirmed from Bangladesh National Herbarium, Dhaka by comparing with their archived voucher specimen and the register number is *Bacopa monnieri* - 46009. The aerial parts of the plant were separated and washed thoroughly. The plants were then kept in a warm dry place (with adequate circulation of air), away from direct sunlight, for two weeks to dry. Completely dried plant material was ground into coarse powder by using a knife mill (0.86 $\mu$ m). The obtained powdered plant material was subjected to maceration process at room temperature with water (500ml), 98% ethanol (500ml) and 99.9% carbon tetrachloride (500ml). About 150gm of coarse powder was soaked with each of the solvent for 21 days in a conical flask covered with aluminium foil and consistent stirring was done. The mixtures were then filtered using filter paper (Whatman Filter paper No. 1) followed by distillation process using rotary evaporator (BuchiRotavapor R-200, Germany) at 78.37<sup>o</sup> C. The aqueous extract was obtained by boiling at 60<sup>o</sup> C in a water bath (JULABO GmbH, Germany). All three extracts were air dried for three days in order to evaporate out any remaining solvent. The residues of aqueous, ethanolic and carbon tetrachloride extracts of *Bacopa monnieri* L. were then collected, weighed and stored in an airtight container. The extractive values of all three extracts were calculated in percentage by using the following formula [55].

$$\text{Extraction value (\%)} = \frac{\text{Weight of dried extract (gm)}}{\text{Weight of powdered crude plant (gm)}} \times 100$$

All drying, milling and extraction processes of crude plant material were done from Pharmacognosy & Phytochemistry Laboratory of Department of Pharmacy, Primeasia University.

### 2.3 Phytochemical screening

Several phytochemical constituents like carbohydrates, triterpenoids, alkaloids, glycosides, tannins, flavonoids, essential oils and other similar secondary metabolites are

present in crude plant material. Hence, different qualitative measures were taken to construct the phytochemical profile of aqueous, ethanolic and carbon tetrachloride extracts of *Bacopa monnieri* L. by using standard protocols [56-58].

### 2.4 Experimental Animals

Swiss albino mice (Male) weighing 30-35 gm were collected from the Department of Pharmacy, Jahangirnagar University, Dhaka, Bangladesh. The animals were housed in a separate animal room at the Department of Pharmacy, Primeasia University where they were kept in polypropylene cages in groups of six mice per cage, maintaining a temperature of about 25  $\pm$  2<sup>o</sup>C with a 12-hour light-dark cycle. All animals were allowed to acclimatize for one week with free access to standard laboratory animal feed and water *ad libitum* prior to the experiment. They were fasted for 24 hours with free access to water only before the experiment [59]. All surgical procedures were performed under isoflurane (5% in 100% oxygen) anesthesia with an effort to minimize pain. The Guide for the Care and Use of Laboratory Animals (NIH publication No: 85-23, revised in 1985) were followed for animal care and research protocols. The experimental procedures were approved by the Biomedical Research Center, University of Dhaka, Bangladesh.

### 2.5 Induction of gastric ulcer

The animals were divided into nine groups (n = 6). The normal group (Group I) received 0.2% tween 80 as vehicle (0.5ml/100gm body weight) by oral gavage. The positive control group (Group II) received oral dose of omeprazole [60] in 0.2% tween 80 (v/v) as reference drug (20mg/kg of body weight p.o.) and all the other test groups (Groups IV - IX) received aqueous, ethanolic and carbon tetrachloride extracts of *B. monnieri* at doses of 200 and 400 mg/kg (b.w. p.o) [45] in 0.2% tween 80v/v (0.5ml/100gm body weight) as a pretreatment. One hour later of the

pretreatment, all the test groups (Groups II - IX) were subjected to induction of gastric ulcer by receiving absolute ethanol (0.5ml/100gm body weight) by oral gavage. After one hour, the mice were euthanized (sacrificed under anesthesia) and their stomachs were dissected via cervical dislocation. The protocol of gastric damage induced by ethanol has been taken from previously established methods with a little modification [61, 62]. The detail of treatment groups and experimental protocol are given below:

Groups	Treatment
<b>Group I</b>	0.5 ml/100gm 0.2% Tween 80, p.o.; (Normal control)
<b>Group II</b>	0.5 ml/100gm 0.2% Tween 80, p.o. + 5 ml/kg absolute ethanol p.o.; (Ulcer control)
<b>Group III</b>	20 mg/kg body weight omeprazole in 0.2% Tween 80, p.o. + 0.5 ml/100gm absolute ethanol p.o. (Positive control)
<b>Group IV</b>	200 mg/kg body weight aqueous extract of <i>Bacopa monnieri</i> in 0.2% Tween 80, p.o + 0.5 ml/100gm absolute ethanol p.o.
<b>Group V</b>	400 mg/kg body weight aqueous extract of <i>Bacopa monnieri</i> in 0.2% Tween 80, p.o + 0.5 ml/100gm absolute ethanol p.o.
<b>Group VI</b>	200 mg/kg body weight ethanolic extract of <i>Bacopa monnieri</i> in 0.2% Tween 80, p.o + 0.5 ml/100gm absolute ethanol p.o.
<b>Group VII</b>	400 mg/kg body weight ethanolic extract of <i>Bacopa monnieri</i> in 0.2% Tween 80, p.o + 0.5 ml/100gm absolute ethanol p.o.

**Group VIII** 200 mg/kg body weight carbon tetrachloride extract of *Bacopa monnieri* in 0.2% Tween 80, p.o + 0.5 ml/100gm absolute ethanol p.o.

**Group IX** 400 mg/kg body weight carbon tetrachloride extract of *Bacopa monnieri* in 0.2% Tween 80, p.o + 0.5 ml/100gm absolute ethanol p.o.

**2.6 Evaluation of antiulcerogenic activity:**

**Determination of Ulcer Index (UI) and percentage of ulcer protection**

The stomachs of mice were opened along the greater curvature followed by washing with physiological saline (0.9% NaCl solution) to remove gastric contents and then subjected to examination by a blinded pathologist for gross macroscopic lesions under a magnifying glass. For gross pathology, the degree of gastric mucosal damage was evaluated based on a scoring system that involved number and severity of gastric lesions as described by previously established method [63]. The scoring for ulcer was accounted as given below:

Condition	Scores
Normal stomach	0
Red coloration	0.5
Spot ulcer	1
Hemorrhagic streak	1.5
Ulcers	2
Perforations	3

The mean ulcer score for each group of animals was calculated and expressed as ulcer index (UI) [64]. Later on, the protection of ulcer was calculated and expressed in percentage [65]. The formula for calculating UI and percentage of ulcer protection are given below:

**Calculation of ulcer index**

$$UI = UN + US + UP \times 10^{-1}$$

Where,

UI = ulcer index

UN = Average number of ulcer per animal group

US = Average of severity score

UP =Percentage of animal with ulcer

### Calculation of % of ulcer protection

$$\text{Percentage protection} = \frac{\text{Control mean ulcer index} - \text{Test mean ulcer index}}{\text{Control mean ulcer index}} \times 100$$

### 2.7 Histopathological examinations and microscopic scoring of gastric damage

Histology of stomach of each group of animals was done by isolating the organ and fixing it in freshly prepared 10% neutral buffered formalin at 4°C for 24 hours. The tissue specimens were washed and dehydrated by alcohol. Later on, they were cleared in xylene and embedded in paraffin in hot air oven at a temperature of 56<sup>0</sup> C for 24 hours. Prior to histopathological examination under the light microscope (LeicaMicrosystems, Germany), the paraffin blocks were cut into tissue sections (5µm thickness) and were subjected to staining with hematoxylin and eosin (H&E) stains [66]. All histopathologic procedures were conducted in Exim Bank Hospital, Department of histopathology, Dhaka, Bangladesh. In order to avoid any bias, a qualified observer (who had been unaware of the identity of samples) performed the evaluation of histopathological tests.

Evaluation of microscopic damage score of gastric lesions was done based on a scale of 0 – 14 according to the criteria reported by Laine and Weinstein [67]. In brief, 1cm of gastric tissue segment was taken into account for examination by observing epithelial cell loss (giving a score of 0-3), edema in mucosal area (giving a score of 0-4), hemorrhagic damage (giving a score of 0-4) and

presence of inflammatory & infiltrated cells (giving a score of 0-3).

### 2.8 Statistical analysis

All experimental data were presented as mean ± SEM of the mean (n = 6). Statistical analysis was done for the comparison between control and treated groups by using one-way analysis of variance (GraphPad Instat3). Statistically significant differences of the P-value between the groups were assessed by employing Dunnett’s test. A value of P<0.05 was considered statistically significant.

## 3. Results

### 3.1 Extractive values of different extracts of *Bacopa monnieri*

In the present study, three different extracts of *Bacopa monnieri L.* were prepared using water, ethanol and carbon tetrachloride solvent system. The extractive values of the different solvent system were determined in percentage as given in Table 1. The ethanolic extract showed maximum extractive value (4%) while the minimum extractive value was obtained by carbon tetrachloride solvent system (2%). In the present investigation, different colored extracts were obtained (Table 1).

**Table 1:** Extractive value (in percentage) and color of *Bacopa monnieri L.*

Solvents	Weight of dried plant (g)	Weight of dried extract (g)	Colors of extract	Extractive value (%)
Water	200	6.54	Dark brown	3.37
Ethanol	200	8.23	Dark green	4
Carbon tetrachloride	200	4	Light green	2

### 3.2 Qualitative phytochemical analysis

Preliminary phytochemical screening of *Bacopa monnieri L.* showed presence of phytochemical constituents in the different extracts (water, ethanolic and carbon tetrachloride). Qualitative phytochemical analysis found different important chemical compounds like alkaloids,

flavonoids, phenols, tannins, steroids and terpenoids in all three extracts as shown in Table 2.

**Table 2:** Analysis of phytochemical screening of *Bacopa monnieri L.* in three different extracting solvents.

Phytochemical tests	Extracting solvents		
	Water	Ethanol	Carbon tetrachloride
Alkaloids	+	+	+
Flavonoids	+	+	+
Phenols	+	+	+
Tannins	+	+	+
Glycosides	+	-	+
Steroids	+	+	+
Terpenoids	+	+	+
Saponin	-	-	-

+ = Present, - = Absent

### 3.3 Effect of aqueous, ethanolic and carbon tetrachloride extracts of *Bacopa monnieri L.* on ethanol-induced gastric injury in mice

#### Evaluation of ulcer index and percentage protection

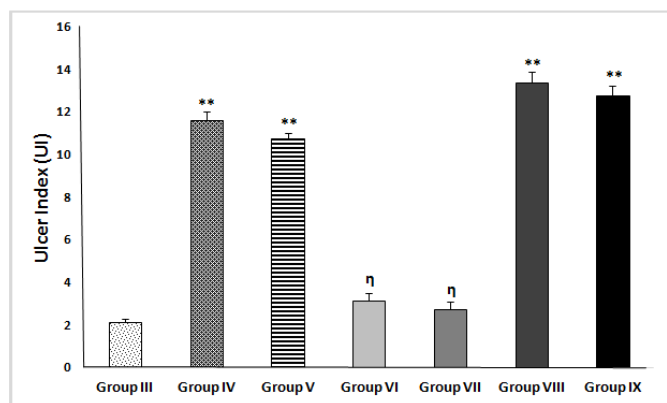
The severity of the gastric injury was explored based on macroscopic damage scores done by gross evaluation of stomach of mice. It was found that oral administration of absolute ethanol (5 ml/kg p.o.) caused severe gastric injury with high UI score when compared with normal control group (treated with 0.2% tween 80). The values of ulcer index (UI) and percentage protection obtained by different animal groups treated with aqueous, ethanolic and carbon tetrachloride extracts of *B. monnieri* are demonstrated in Table 3. Pretreatment with both doses (200mg/kg and 400mg/kg) of all three extracts (except CTCEBM of 200mg/kg) showed significant result ( $p < 0.01$ ) for UI value when compared with ulcer control (Group II). On the other hand, pretreatment with CTCEBM (200mg/kg and 400mg/kg p.o.) exhibited lowest UI score with the maximum ulcerative area (8% and 12% ulcer protection). However, a moderate protection against gastric injury was found by pretreatment with aqueous extract of *B. monnieri* (20% and 26% ulcer protection for the doses of 200mg/kg and

400mg/kg p.o. respectively). Interestingly, pretreatment with EEBP (200mg/kg and 400mg/kg p.o.) showed lowest score of gross gastric mucosal damage ( $3.13 \pm 0.38$  and  $2.75 \pm 0.32$ ) and protected largest area of gastric damage (78% and 81%) when compared with ulcer control. This result was close to the score evidenced by the reference anti-ulcer drug (omeprazole, 20mg/kg p.o.) showing 85% ulcer protection (Figure 1). As demonstrated in Figure 1, no significant difference was found in the UI values between EEBP (200mg/kg and 400mg/kg p.o.) and omeprazole (20mg/kg p.o.). Nevertheless, both aqueous and carbon tetrachloride extracts of *B. monnieri* showed significant difference ( $p < 0.01$ ) in UI values when compared with the reference drug (omeprazole, 20mg/kg).

**Table 3:** Effect of different extracts of *B. monnieri* on changes in ulcer index and % of ulcer protection in mice with ethanol-induced gastric injury.

Groups	Treatments	Doses	Ulcer Index & % Protection	
			Mean $\pm$ S.E.M (n=4)	% Protection
Group I	Normal Control (0.2% tween 80 only)	0.5ml/100gm	0.5 $\pm$ 0.20	-
Group II	Ulcer Control (absolute ethanol only)	0.5ml/100gm	14.5 $\pm$ 0.35**a	-
Group III	Omeprazole	20 mg/kg	2.13 $\pm$ 0.13**b	85
Group IV	AEBM	200 mg/kg	11.63 $\pm$ 0.38**b	20
Group V	AEBM	400 mg/kg	10.75 $\pm$ 0.25**b	26
Group VI	EEBM	200 mg/kg	3.13 $\pm$ 0.38**b	78
Group VII	EEBM	400 mg/kg	2.75 $\pm$ 0.32**b	81
Group VIII	CTCEBM	200 mg/kg	13.38 $\pm$ 0.47ab	8
Group IX	CTCEBM	400 mg/kg	12.75 $\pm$ 0.48**b	12

Each value is Mean  $\pm$  S.E.M (n=6). AEBM =Aqueous Extract of *B. monnieri*, EEBM = ethanolic extract of *B. monnieri* and CTCEBM = Carbon tetrachloride Extract of *B. monnieri*. (\*) indicates statistically significant difference from respective group using one way analysis of variance, followed by Dunnett's multiple comparison test (\*\* $p < 0.01$ ). a = when compared with normal control, b = when compared with ulcer control.



**Figure 1:** Effect of *B. monnieri* extracts on ulcer index in mice with ethanol-induced gastric injury. The values are expressed as Mean  $\pm$  S.E.M ( $n=6$ ) where (\*) indicates statistically significant while ( $\eta$ ) indicates statistically insignificant difference from respective group (Group III) using one way analysis of variance, followed by Dunnett's multiple comparison test (\*\* $p < 0.01$ ). **Group III** = 20 mg/kg body weight omeprazole in 0.2% Tween 80, p.o + 5 ml/kg absolute ethanol p.o.; **Group IV** = 200 mg/kg body weight aqueous extract of *Bacopa monnieri* in 0.2% Tween 80, p.o + 5 ml/kg absolute ethanol p.o.; **Group V** = 400 mg/kg body weight aqueous extract of *Bacopa monnieri* in 0.2% Tween 80, p.o + 5 ml/kg absolute ethanol p.o.; **Group VI** = 200 mg/kg body weight ethanolic extract of *Bacopa monnieri* in 0.2% Tween 80, p.o + 5 ml/kg absolute ethanol p.o.; **Group VII** = 400 mg/kg body weight ethanolic extract of *Bacopa monnieri* in 0.2% Tween 80, p.o + 5 ml/kg absolute ethanol p.o.; **Group VIII** = 200 mg/kg body weight carbon tetrachloride extract of *Bacopa monnieri* in 0.2% Tween 80, p.o + 5 ml/kg absolute ethanol p.o.; **Group IX** = 400 mg/kg body weight carbon tetrachloride extract of *Bacopa monnieri* in 0.2% Tween 80, p.o + 5 ml/kg absolute ethanol p.o.

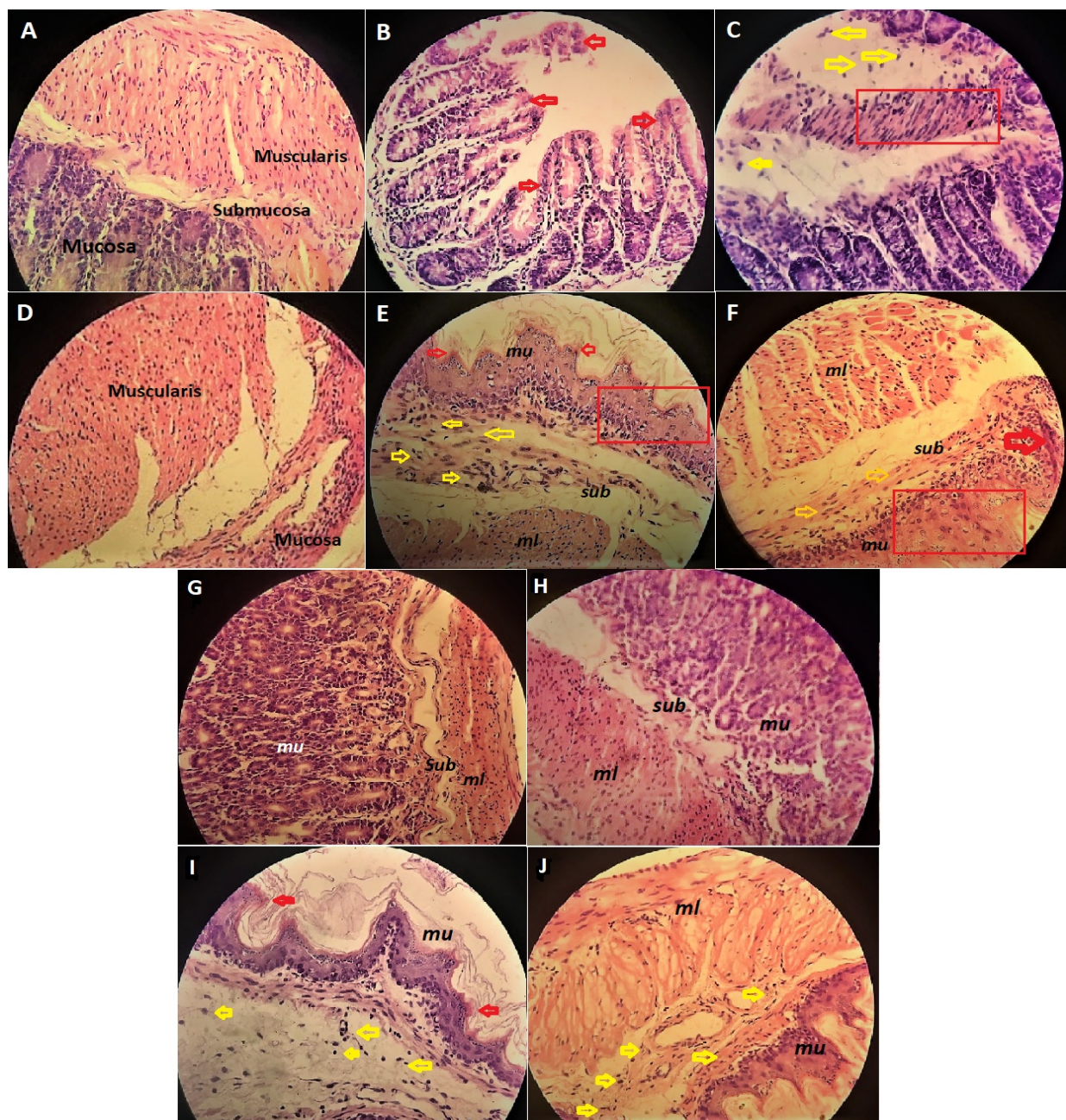
### 3.4 Effect of different extracts of *B. monnieri* on histopathology of stomach of experimental mice

The present study further investigated whether the ethanol-induced gastric models promoted histopathologic

damage when compared to normal control and the extracts of *Bacopa monnieri* L. protected gastric damage when compared to ulcer control. Samples of gastric sections from each group displayed histopathologic changes as shown in the Figure 2. The Figure 2A demonstrated a section from the stomach of normal control mouse received only 0.2% Tween 80 vehicle only without induction of ulcer. This section exhibits normal architecture of mucosa (mu) with intact epithelial surface, submucosa (sub) and muscularis (ml) layers. With respect to the normal control the ulcer control (Figure 2B & C) showed a diverse morphology of tissue that was characterized by mucosal lesions with marked hemorrhage (indicated by red arrows). In addition, the mucosa was infiltrated by inflammatory cells (indicated by yellow arrows) that also extended to the submucosa which also displayed extensive edema. The histology of standard group (Figure 2D) receiving omeprazole (20 mg/kg b.w. p.o.) revealed attenuated morphological modifications, diminished inflammatory cell invasion and mucosal preservation. Pretreatment with aqueous extract of *B. monnieri* (200 mg/kg and 400 mg/kg b.w. p.o.) failed to preserve cellular morphology at higher extent as it showed minor sign of hemorrhage (marked in red arrows), and considerable loss of epithelial cells (marked in red square) along with cellular infiltration (marked in yellow arrows) and extensive edema in submucosal area (Figure 2E & F). However, histology of *B. monnieri* extract of 400 mg/kg exhibited slightly better morphology than the extract of 200 mg/kg in terms of the extent of cellular infiltration in the area of submucosa (Figure 2F). In contrast, administration of carbon tetrachloride extract of *B. monnieri* (200 mg/kg and 400 mg/kg b.w. p.o.) could not preserve cellular morphology at higher extent as minor sign of hemorrhage (marked in red arrows) was found in histopathological results along with considerable loss of epithelial cells (marked in red square) and cellular

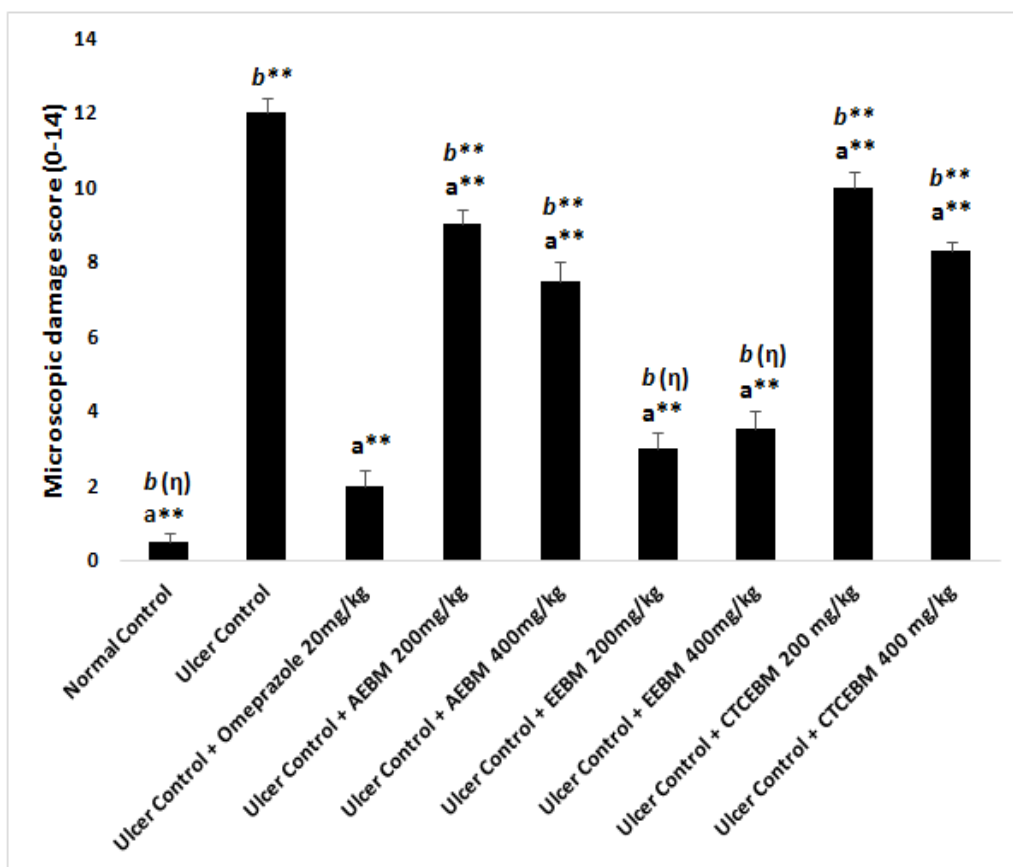
infiltration (marked in yellow arrows) (Figure 2G & H). Interestingly, pretreatment with ethanolic extract of *B. monnieri* (200 mg/kg and 400 mg/kg b.w. p.o.) preserved the architecture of the gastric wall (Figure 2I & J).

Based on the results of mean microscopic damage score, as demonstrated in Figure 3, the ethanol control mice exhibited highest score (12 out of 14) showing severe mucosal injury. Significant difference (\*\* $p < 0.01$ ) was found between ulcer control group and all other treatment groups. Pre-treated with aqueous and carbon tetrachloride extracts of *B. monnieri* before being given ethanol (0.5ml/kg b.w. p.o.) had shown very high score indicating significant difference (\*\* $p < 0.01$ ) when compared with group pre-treated by omeprazole (20 mg/kg b.w. p.o.). However, there were no significant differences in microscopic damage scores between ethanolic extracts of 200 and 400 mg/kg of *B. monnieri* (3.5 and 3 out of 14 respectively) and the reference drug (omeprazole) (2 out of 14). This significantly reduced areas of gastric ulcer formation showing flattening of gastric mucosal folds.



**Figure 2:** Histopathological changes in the stomach representing photomicrographs of sections from gastric walls of different groups of ulcer induced experimental animals. **A: Group I** = Normal control; **B & C: Group II** = Ulcer control; **D: Group III** = 20 mg/kg body weight omeprazole in 0.2% Tween 80, p.o + 5 ml/kg absolute ethanol p.o.; **E:Group IV** = 200 mg/kg body weight

aqueous extract of *Bacopa monnieri* in 0.2% Tween 80, p.o + 5 ml/kg absolute ethanol p.o.; **F:Group V** = 400 mg/kg body weight aqueous extract of *Bacopa monnieri* in 0.2% Tween 80, p.o + 5 ml/kg absolute ethanol p.o.; **G:Group VI** = 200 mg/kg body weight ethanolic extract of *Bacopa monnieri* in 0.2% Tween 80, p.o + 5 ml/kg absolute ethanol p.o.; **H:Group VII** = 400 mg/kg body



**Figure 3:** Microscopic damage scores (0-14) expressed as Mean ± S.E.M.; n=6. Normal control = 5 ml/kg 0.2% Tween 80, p.o.; Ulcer Control = 5 ml/kg 0.2% Tween 80, p.o. + 5 ml/kg absolute ethanol p.o. AEBM =Aqueous Extract of *B. monnieri*, EEBM = ethanolic extract of *B. monnieri* and CTCEBM = Carbon tetrachloride Extract of *B. monnieri*. (\*) indicates statistically significant while (η) indicates statistically insignificant difference from respective groups using one way analysis of variance, followed by Dunnett’s multiple comparison test (\*\* $p < 0.01$ ). a = when compared with ulcer control, b = when compared with omeprazole.

#### 4. Discussion

A wide variety of herbal drugs have been approved by Food and Drug Administration (FDA) that are currently available in global market. These herbal remedies have been recognized for their effectiveness against several ailments due to the presence of significant phytochemical constituents [68-70]. The present investigation involved phytochemical analysis of three different extracts including water, ethanol and carbon tetrachloride of *Bacopa monnieri L.* Extract of different solvent medium exhibited variation in availability of phytochemical constituents. Both aqueous and carbon tetra chloride

extracts of *Bacopamonnieri L.* showed the presence of useful phytochemical constituents including alkaloids, flavonoids, phenols, steroids, glycosides, tannins and terpenoids. In contrast, all of these phytochemical constituents are present in the ethanolic extract of the plant except for glycosides. However, saponin was not found in the extract of any of the solvent medium. Such observation regarding phytochemical screening of aqueous and ethanolic extracts of *Bacopa monnieri L.* was observed in previous study by Singh *et al.*, 2012 [71].

Gastric ulcer has been recognized as global concern for many years and is characterized as inflammation in gastric mucosa. Medicinal plants containing flavonoids and phenols are significantly used as protective agents against ulcers [62, 72]. Our present study highlights the protective activity of various extracts of *Bacopa monnieri L.* against gastric ulcer. The study revealed variation in anti-ulcerogenic effect of three different extracts (aqueous, ethanolic and carbon tetrachloride) of *B. monnieri* against ethanol-induced gastric injury in mice. Due to presence of flavonoids in all three extracts of the plant, moderate to extensive protection against gastric ulcer was observed. Based on previous report, ethanol induced gastric lesions cause mucosal damage by producing considerable inflammatory cell infiltration and tissue injury [73-75]. Such models have been widely used for the purpose of evaluation of gastroprotective activity [76-80]. As per our histopathological results, exposure of ethanol to gastric mucosa inflicted gastric injury by disruption of mucosal and submucosal layers. In addition, the histopathological results and microscopic damage scores of the treated animals with aqueous and carbon tetrachloride extracts of *B. monnieri* exhibited moderate to poor protection against gastric ulcers when compared with treatment with standard drug (Omeprazole). On the other hand, the ethanolic extract of *B. monnieri* (200 & 400 mg/kg b.w.) potentially regulated the inflammatory response that

correspond to omeprazole (20 mg/kg b.w.) as evidenced by reduced ulcer index and microscopic score along with the results of histopathological evaluation. Although all three extracts contain flavonoids and phenols, the present outcome of our study suggests that the presence of high flavonoid and phenolic contents may favor the ethanolic extract of *B. monnieri* to possess significant protective effect against ulcer when compared with other two extracts.

## 5. Conclusion

In conclusion, the present study evidently showed anti-ulcerogenic activity of ethanolic extract of *Bacopa monnieri L.* against ethanol-induced gastric ulcer in mice model. This extract exhibited dose-dependent therapeutic effect. As a result, high dose (400 mg/kg b.w) of ethanolic extract of *B. monnieri* showed significant protection against gastric ulcer. At this dose, the therapeutic efficacy of the extract was observed to be same as omeprazole (20 mg/kg b.w.). Hence, with respect to our present analysis, it can be stated that ethanol could be a suitable medium to obtain *Bacopa monnieri L.* extract which can be considered as a promising curative for the treatment of gastric ulcer.

## Ethics approval

All experimental procedures were approved by the Biomedical Research Center, University of Dhaka, Bangladesh.

## Acknowledgments

Laboratory support from the Department of Pharmacy, Primeasia University, Dhaka, Bangladesh and Phytochemical Laboratory of University of Dhaka, Dhaka, Bangladesh is gratefully acknowledged.

## Abbreviations

*B. monnieri L.* = *Bacopa monnieri* Linn.

UI = Ulcer index

AEBM = Aqueous Extract of *B. monnieri*

EEBM = ethanolic extract of *B. monnieri*

CTCEBM = Carbon tetrachloride Extract of *B. monnieri*.

### Competing interest

The authors declare that they have no competing interests.

### Funding

The present research was conducted for one year. The cost of research was high and we did not have grant or received any departmental funding.

### Consent for publication

We confirm that this manuscript has not been published elsewhere and is not under consideration by another journal. All authors have approved the manuscript and agreed with submission to International Journal of Medical Science and Innovative Research (IJMSIR).

### Availability of data and materials

All data generated or analysed during this study are included in this published article.

### Authors' contributions

Rubaba Karim made substantial contributions to conception design and conduction of research. Sabiha Akter, Najia Sultana Shuchi, Mst. Maliha Tabachasum Madhuri, and Md. Nazmul Hossain performed all of the experiments in the laboratory. Data collection, statistical analysis and interpretation were done by Rubaba Karim and Ashfia Fatima Khan. Article was written by Rubaba Karim. Critical revision of the article was done by Ashfia Fatima Khan. All Authors read and approved the final manuscripts.

### References

1. Sparreboom A, Cox MC, Acharya MR, Figg WD. Herbal remedies in the United States: potential adverse interactions with anticancer agents. *Journal of Clinical Oncology*. 2004 Jun 15;22(12):2489-503.
2. In the wealth of India: A Dictionary of Indian Raw Materials and Industrial Products. New Delhi, India. 1998; 2: 116-118.
3. Al-Snafi AE. The pharmacology of Bacopamonniera. A review, *Int J PharmaSci Res*. 2013;4:154-9.
4. Russo A, Borrelli F. Bacopa monniera, a reputed nootropic plant: an overview. *Phytomedicine*. 2005 Apr 20;12(4):305-17.
5. Chopra RN, Nayar L and Chopra IC. Glossary of Indian Medicinal Plants, Vol 32, Council of Scientific and Industrial Research, New Delhi 1956.
6. Sastri MS, Dhalla NS, Malhotra CL. Chemical investigation of *Herpestismonniera* Linn (Brahmi). *Ind J Pharmacol*. 1959;21:303-4.
7. Chatterji N, Rastogi RP and Dhar ML. Chemical examination of *Bacopa monniera* Wettst: partitioning of chemical constituents. *India J Chem* 1965; 3: 24-29.
8. Garay S, Mahato SB, Ohtani K and Yamaski K. Dammarane-type triterpenoidsaponins from *Bacopa monniera*. *Phytochemistry* 1996; 42: 815-820.
9. Chakravarty AK, Sarkar T, Nakane T, Kawahara N, Masuda K and Shiojima K. Bacopaside I and II: two pseudojujubogeninglycosides from *Bacopa monniera*. *Phytochemistry* 2001; 58: 553-556.
10. Chakravarty AK, Sarkar T, Nakane T, Kawahara N and Masuda K. New Phenylethanoid glycosides from *Bacopa monniera*. *Chem Pharm Bull* 2002; 50: 1616-1618.
11. Chakravarty AK, Garai S, Masuda K, Nakane T and Kawahara N. Bacopasides III-IVP; three new triterpenoid glycosides from *Bacopa monniera*. *Chem Pharm Bull* 2003; 51: 215-21
12. Avanigadda S and Vangalapati M . A Review on pharmacological studies of *Bacopa monniera*. *J Chem Bio PhySci* 2011;1(2): 250 – 259.
13. Thomas RB, Joy S, Ajayan MS, Paulose CS. Neuroprotective Potential of *Bacopa monnieri* and Bacoside A against dopamine receptor dysfunction in

- the cerebral cortex of neonatal hypoglycaemic rats. *Cell Mol Neurobiol.* 2013;33(8):1065–74.
14. Saini N, Singh D, Sandhir R. Neuroprotective effects of Bacopa monnieri in experimental model of dementia. *Neurochem Res.* 2012;37(9):1928–37.
15. Kamkaew N, Scholfield CN, Ingkaninan K, Taepavarapruk N, Chootip K. Bacopa monnieri increases cerebral blood flow in rat independent of blood pressure. *Phytother Res.* 2013;27(1):135–8.
16. Priyanka HP, Bala P, Ankisetipalle S, ThyagaRajan S. Bacopa monnieri and L-deprenyl differentially enhance the activities of antioxidant enzymes and the expression of tyrosine hydroxylase and nerve growth factor via ERK 1/2 and NF-kB pathways in the spleen of female Wistar rats. *Neurochem Res.* 2012;38(1):141–52.
17. Russo A, Borrelli F, Campisi A, Acquaviva R, Raciti G, Vanella A. Nitric oxidederelated toxicity in cultured astrocytes: Effect of Bacopa monniera. *Life Sci.* 2003;73:1517–26.
18. Pawar R, Gopalakrishnan C, Bhutani KK. Dammaranetriterpenesaponin from Bacopa monniera as the superoxide Inhibitor in polymorphonuclear cells. *Planta Med.* 2001;67:752–4.
19. Jadiya P, Khan A, Sammi SR, Kaur S, Mir SS, Nazir A. Anti-parkinsonian effects of Bacopa monnieri: insights from transgenic and pharmacological Caenorhabditiselegans models of Parkinson's disease. *Biochem Biophys Res Commun.* 2011;413(4):605–10.
20. Menon BR, Rathi MA, Thirumoorthi L, Gopalakrishnan VK. Potential effect of Bacopamonnieri on nitrobenzene induced liver damage in rats. *Indian J ClinBiochem.* 2010;25(4):401–4.
21. Sairam K, Dorababu M, Goel RK, Bhattacharya SK. Antidepressant activity of standardized extract of Bacopamonniera in experimental models of depression in rats. *Phytomedicine.* 2002;9:207–11.
22. Chowdhuri DK, Parmar D, Kakkar P, Shukla R, Seth PK, Srimal RC. Anti-stress effects of bacosides of Bacopa monnieri: modulation of HSP to expression, Sol and cytochrome P450 activity in rat brain. *Phytother Res.* 2002;16:639–45.
23. Elangovan V, Govindasamy S, Ramamoorthy N, Balasu-bramanian K. In vitro studies on the anticancer activity of Bacopa monniera. *Fitoterapia.* 1995;66:211–5.
24. Mathur A, Verma SK, Purohit R, Singh SK, Mathur D, Prasad G and Dua VK. Pharmacological investigation of Bacopa monnieri on the basis of antioxidant, antimicrobial and anti-inflammatory properties. *J Chem Pharm. Res* 2010, 2(6):191-198.
25. Azad AK, Awang M, Rahman MM. Phytochemical and microbiological evaluation of a local medicinal plant Bacopa monnieri (L.) Penn. *International Journal of Current Pharmaceutical Review and Research* 2012;3(3), 66-78.
26. Kar A, Panda S and Bharti S. Relative efficacy of three medicinal plant extracts in the alteration of thyroid hormone concentrations in male mice. *J Ethnopharmacol* 2002;81: 281-285.
27. Akanksha S and Singh SK. Evaluation of anti-fertility potential of Brahmi in male mouse. *Contraception* 2009;79:71-79.
28. Jain P, Khanna NK, Trehan T, Pendse VK, Godhwani JL. Anti-inflammatory effects of an Ayurvedic preparation, BrahmiRasayan, in rodents. *Indian J Exp Biol.* 1994;32:633–6.
29. AjalusSMd, Chakma N, Rahman M, Salahuddin M and Kumar ss. Assessment of analgesic ,antidiarrhoeal and cytotoxic activity of ethanolic

- extract of the whole plant of *Bacopamonnieri* Linn .  
*Int Res J of Pharmacy* 2013;3(10):98-101.
30. Sairam K, Rao VC, Babu DM, Goel KR. Prophylactic and curative effects of *Bacopa monniera* in gastric ulcer models. *Phytomedicine*. 2001;8:423–30.
31. Brown LF, Wilson DE. Gastroduodenal ulcers: causes, diagnosis, prevention and treatment. *ComprTher*. 1999;25(1):30–38.
32. Maity P, Biswas K, Roy S, Banerjee RK, Bandyopadhyay U. Smoking and the pathogenesis of gastroduodenal ulcer—recent mechanistic update. *Molecular and cellular biochemistry*. 2003 Nov 1;253(1-2):329-38.
33. Cowan WK. Genetics of duodenal and gastric ulcer. *ClinGastroenterol*. 1973;2(3):539–546.
34. Laine L, Weinstein WM. Histology of alcoholic hemorrhagic “gastritis”: a prospective evaluation. *Gastroenterology*. 1988 Jun 1;94(6):1254-62.
35. Yeomans ND, Hawkey CJ, Brailsford W, Næsdal J. Gastroduodenal toxicity of low-dose acetylsalicylic acid: a comparison with non-steroidal anti-inflammatory drugs. *Current medical research and opinion*. 2009 Nov 1;25(11):2785-93.
36. Yuan L, Wang JH, Sun TM. Total synthesis and anticancer activity studies of the stereoisomers of asperphenamate and patriscabratine. *Chinese Chemical Letters*. 2010 Feb 1;21(2):155-8.
37. Itatsu T, Nagahara A, Hojo M, Miyazaki A, Murai T, Nakajima M, Watanabe S. Use of selective serotonin reuptake inhibitors and upper gastrointestinal disease. *Internal Medicine*. 2011;50(7):713-7.
38. Sjøberg T, Hofstad B, Sandvik L, Johansen M, Lygren I. Risk factors for peptic ulcer bleeding. *Tidsskrift for den Norske lægeforening: tidsskrift for praktiskmedicin, nyraekke*. 2010 Jun;130(11):1135-9.
39. Franke A, Teysen S, Singer MV. Alcohol-related diseases of the esophagus and stomach. *Digestive Diseases*. 2005;23(3-4):204-13.
40. Shaker E, Mahmoud H, Mnaa S. Anti-inflammatory and anti-ulcer activity of the extract from *Alhagimaurosum* (camelthorn). *Food and Chemical Toxicology*. 2010 Oct 1;48(10):2785-90.
41. Davenport HW. Destruction of the gastric mucosal barrier by detergents and urea. *Gastroenterology*. 1968 Feb 1;54(2):175-81.
42. Jainu M, Mohan KV, Devi CS. Gastroprotective effect of *Cissusquadrangularis* extract in rats with experimentally induced ulcer. *Indian Journal of Medical Research*. 2006 Jun 1;123(6):799.
43. Al Batran R, Al-Bayat F, Al-Obaidi MM, Abdulkader AM, Hadi HA, Ali HM, Abdulla MA. In vivo antioxidant and antiulcer activity of *Parkiaspeciosa* ethanolic leaf extract against ethanol-induced gastric ulcer in rats. *PloS one*. 2013 May 28;8(5):e64751.
44. Corrado B, Marco T, Colucci R, Fornai M, Antonioli L, Ghisu N and Tacca MD: Role of coxibs in the strategies for gastrointestinal protection in patients requiring chronic non-steroidal anti-inflammatory therapy. *Pharmacology Research* 2009; 59: 90-100.
45. Hossain H, Al-Mansur A, Akter S, Sara U, Ahmed MR, Jahangir AA. Evaluation of anti-inflammatory activity and total tannin content from the leaves of *Bacopa monnieri* (Linn.). *International Journal of Pharmaceutical Sciences and Research*. 2014 Apr 1;5(4):1246.
46. Abdelwahab SI, Taha MM, Abdulla MA, et al. Gastroprotective mechanism of *Bauhinia thonningii* Schum. *J Ethnopharmacol*. 2013; 148(1):277–286

47. Omar H, Nordin N, Hassandarvish P, Hajrezaie M, Azizan AH, Fadaeinasab M, Majid NA, Abdulla MA, Hashim NM, Ali HM. Methanol leaf extract of *Actinodaphnesesquipedalis* (Lauraceae) enhances gastric defense against ethanol-induced ulcer in rats. *Drug design, development and therapy*. 2017;11:1353.
48. Golbabapour S, Hajrezaie M, Hassandarvish P, et al. Acute toxicity and gastroprotective role of *M. pruriens* in ethanol-induced gastric mucosal injuries in rats. *Biomed Res Int*. 2013;2013:974185.
49. Bandyopadhyay D, Biswas K, Bhattacharyya M, Reiter RJ, Banerjee RK. Involvement of reactive oxygen species in gastric ulceration: protection by melatonin. *Indian J Exp Biol*. 2002;40(6):693–705.
50. Mota KS, Dias GE, Pinto ME, et al. Flavonoids with gastroprotective activity. *Molecules*. 2009;14(3):979–1012.
51. Dorababu M, Prabha T, Priyambada S, Agrawal VK, Aryya NC, Goel RK. Effect of *Bacopa monniera* and *Azadirachta indica* on gastric ulceration and healing in experimental NIDDM rats. *Ind. J Exp Biol.*, 42, 2004, 389-397.
52. Rao CV, Sairam K, Goel RK. Experimental evaluation of *Bocopa monniera* on rat gastric ulceration and secretion. *Indian Journal of Physiology and Pharmacology*. 2000 Oct 24;44(4):435-41.
53. Dharmani P, Palit G. Exploring Indian medicinal plants for antiulcer activity. *Indian journal of pharmacology*. 2006 Mar 1;38(2):95.
54. Sairam K, Rao CV, Babu MD, Goel RK. Prophylactic and curative effects of *Bacopa monniera* in gastric ulcer models. *Phytomedicine*. 2001 Jan 1;8(6):423-30.
55. SS P, Jadhav MG, Deokar TG. Study of Phytochemical Screening, Physicochemical Analysis and Antimicrobial Activity of *Bacopamonneri* (L) Extracts. *International Journal of Pharmaceutical and Clinical Research* 2016; 8(8): 1222-1229.
56. Tiwari P, Kumar B, Kaur M, Kaur G, Kaur H. Phytochemical screening and extraction: a review. *International epharmaceuticasciencia*. 2011 Mar;1(1):98-106.
57. Yadav M, Chatterji S, Gupta SK, Watal G. Preliminary phytochemical screening of six medicinal plants used in traditional medicine. *International journal of Pharmacy and Pharmaceutical sciences*. 2014; 6(5):539-542.
58. Usman H, Abdulrahman FI, Usman A. Qualitative phytochemical screening and in vitro antimicrobial effects of methanol stem bark extract of *Ficusthonningii* (Moraceae). *African Journal of Traditional, Complementary and Alternative Medicines*. 2009; 6(3):289-295.
59. Mahmood AA, Mariod AA, Al-Bayaty F, Abdel-Wahab SI. Anti-ulcerogenic activity of *Gynuraprocumbens* leaf extract against experimentally-induced gastric lesions in rats. *Journal of Medicinal Plants Research*. 2010 Apr 18;4(8):685-91.
60. Omar H, Nordin N, Hassandarvish P, Hajrezaie M, Azizan AH, Fadaeinasab M, Majid NA, Abdulla MA, Hashim NM, Ali HM. Methanol leaf extract of *Actinodaphnesesquipedalis* (Lauraceae) enhances gastric defense against ethanol-induced ulcer in rats. *Drug design, development and therapy*. 2017;11:1353.
61. Abdulla MA, Ahmed KA, Al-Bayaty FH, Masood Y. Gastroprotective effect of *Phyllanthusniruri* leaf extract against ethanol-induced gastric mucosal injury in rats. *African Journal of Pharmacy and Pharmacology*. 2010 May 31;4(5):226-30.
62. Boligon AA, de Freitas RB, de Brum TF, Waczuk EP, Klimaczewski CV, de Ávila DS, Athayde ML, de

- FreitasBauermann L. Antiulcerogenic activity of *Scutiabuxifolia* on gastric ulcers induced by ethanol in rats. *ActaPharmaceuticaSinica B*. 2014 Oct 1;4(5):358-67.
63. Brzozowski T, Konturek PC, Konturek SJ, Kwiecien S, Pajdo R, Brzozowska I, Hahn EG. Involvement of endogenous cholecystokinin and somatostatin in gastroprotection induced by intraduodenal fat. *Journal of clinical gastroenterology*. 1998 Jan 1;27:S125-37.
64. Vogel GH. *Drug discovery and evaluation*. New York: SpringerVerlag Berlin Heidelberg; 2002, p. 868
65. Gupta J, Kumar D, Gupta A. Evaluation of gastric anti-ulcer activity of methanolic extract of *Cayratiatrifolia* in experimental animals. *Asian Pacific Journal of Tropical Disease*. 2012 Apr 1;2(2):99-102.
66. Yam MF, Ang LF, Salman IM, Ameer OZ, Lim V, Ong LM, Ahmad M, Asmawi MZ, Basir R. *Orthosiphonstamineus* leaf extract protects against ethanol-induced gastropathy in rats. *Journal of medicinal food*. 2009 Oct 1;12(5):1089-97.
67. Laine L, Weinstein WM. Histology of alcoholic hemorrhagic "gastritis": a prospective evaluation. *Gastroenterology*. 1988 Jun 1;94(6):1254-62.
68. Licciardi PV, Underwood JR. Plant-derived medicines: a novel class of immunological adjuvants. *International immunopharmacology*. 2011 Mar 1;11(3):390-8.
69. Potterat O, Hamburger M. *Drug discovery and development with plant-derived compounds*. In *Natural Compounds as Drugs Volume I 2008* (pp. 45-118). Birkhäuser Basel.
70. Torres-Urrutia C, Guzman L, Schmeda-Hirschmann G, Moore-Carrasco R, Alarcon M, Astudillo L, Gutierrez M, Carrasco G, Yuri JA, Aranda E, Palomo I. Antiplatelet, anticoagulant, and fibrinolytic activity in vitro of extracts from selected fruits and vegetables. *Blood Coagulation & Fibrinolysis*. 2011 Apr 1;22(3):197-205.
71. Singh SK. Phytochemical analysis of leaf callus of *Bacopa monnieri* L. *Int. J. Sci. Res. Pub*. 2012;2:1-3.
72. Rathee P, Chaudhary H, Rathee S, Rathee D, Kumar V, Kohli K. Mechanism of action of flavonoids as anti-inflammatory agents: a review. *Inflammation & Allergy-Drug Targets (Formerly Current Drug Targets-Inflammation & Allergy)*. 2009 Jul 1;8(3):229-35.
73. Mota CS, Freitas RB, Athayde ML, Boligon AA, Augusti PR, Somacal S, Rocha MP, Bauermann LF. Effect of *Vernoniacognata* on oxidative damage induced by ethanol in rats. *Human & experimental toxicology*. 2011 Jul;30(7):675-84.
74. Gazzieri D, Trevisani M, Springer J, Harrison S, Cottrell GS, Andre E, Nicoletti P, Massi D, Zecchi S, Nosi D, Santucci M. Substance P released by TRPV1-expressing neurons produces reactive oxygen species that mediate ethanol-induced gastric injury. *Free Radical Biology and Medicine*. 2007 Aug 15;43(4):581-9.
75. Liu YZ, Zhou Y, Li D, Wang L, Hu GY, Peng J, Li YJ. Reduction of asymmetric dimethylarginine in the protective effects of rutaecarpine on gastric mucosal injury. *Canadian journal of physiology and pharmacology*. 2008 Oct 2;86(10):675-81.
76. Ineu RP, Pereira ME, Aschner M, Nogueira CW, Zeni G, Rocha JB. Diphenyldiselenide reverses gastric lesions in rats: involvement of oxidative stress. *Food and chemical toxicology*. 2008 Sep 1;46(9):3023-9.
77. Choi EY, Hwang HJ, Kim IH, Nam TJ. Protective effects of a polysaccharide from *Hizikiafusiformis* against ethanol toxicity in rats. *Food and Chemical Toxicology*. 2009 Jan 1;47(1):134-9.

78. Hussaini J, Othman NA, Abdulla MA, Majid NA, Faroq HM, Ismail S. Gastroprotective effects of *Dicranopterislinearis* leaf extract against ethanol-induced gastric mucosal injury in rats. *Scientific Research and Essays*. 2012 May 16;7(18):1761-7.
79. Aziz Ibrahim IA, Qader SW, Abdulla MA, Nimir AR, Abdelwahab SI, Al-Bayaty FH. Effects of *Pithecellobiumjiringa* ethanol extract against ethanol-induced gastric mucosal injuries in Sprague-Dawley rats. *Molecules*. 2012 Mar 6;17(3):2796-811.
80. Hajrezaie M, Salehen N, Karimian H, Zahedifard M, Shams K, Al Batran R, Majid NA, Khalifa SA, Ali HM, El-Seedi H, Abdulla MA. Biochanin a gastroprotective effects in ethanol-induced gastric mucosal ulceration in rats. *PloS one*. 2015 Mar 26;10(3):e0121529.