

Study of surgical management of thyroid swelling with special emphasis on surgical technique for preservation of recurrent laryngeal nerve, external branch of superior laryngeal nerve and parathyroid gland

Manphool Singh Maharia¹, Ramesh Kadela^{1*}, Naresh kumar Gothwal¹, Deep Chand¹

¹Department of ENT, Sardar Patel Medical College, Bikaner, Rajasthan, India

Correspondence Author: Dr. Ramesh Kadela, Department of ENT, Sardar Patel Medical College, Bikaner, Rajasthan, India

Type of Publication: Original Research Paper

Conflicts of Interest: Nil

Abstract

Background: Thyroid swelling is a common presentation in otorhinolaryngology department. This study aims to biochemical, pathological and radiological study to ascertain the nature of thyroid swelling and appropriate surgical management with special emphasis on technique to identify and preserve recurrent laryngeal nerve, external branch of superior laryngeal nerve and parathyroid gland.

Method: This study was conducted at Sardar Patel Medical College, Bikaner from April 2016 to March 2017. Study of surgical management of thyroid swelling with special emphasis on technique for preservation of recurrent laryngeal nerve, external branch of superior laryngeal nerve and parathyroid gland. All collected data were tabulated and statistical analysis by using SPSS software.

Result: Thyroid swelling mostly seen in the female of thirty one to fifty years. Mostly solitary thyroid nodule for which hemi-thyroidectomy done. On histopathological examination mostly reported colloid goitre.

The main indication for surgery in our series was cosmetic problem. The complication like hypoparathyroidism, recurrent laryngeal nerve palsy and external branch of superior laryngeal nerve palsy is very rare.

Conclusion: The result of our study confirms that iatrogenic injury to the parathyroid gland, recurrent laryngeal nerve or its branches can be avoided by seeking, identifying and exposing the nerve and by following its course carefully

Keyword: Thyroid gland, Recurrent laryngeal nerve, Parathyroid gland.

Introduction

Thyroid swelling is a common presentation in Otorhinolaryngology Departments. The mostly clinically detectable thyroid nodules are benign. During the last past two decades, a steep rise in the incidence of differentiated carcinoma of the thyroid gland has been observed worldwide¹.

The bleeding, injury to the recurrent laryngeal nerve, hypoparathyroidism, hypothyroidism, thyrotoxic storm, injury to the superior laryngeal nerve, and infection was major complication of thyroid surgery.

The refinement in surgical techniques, recognition of the presence of parathyroids, recurrent laryngeal nerve (RLN), and protection of the external branch of superior laryngeal nerve (EBSLN) result in lesser morbidity.^{1,2} Mostly the morbidity is due to technical failure to identify the vital structures and the variations in the surgical anatomy when the gland is pathologically enlarged. The RLN is routinely exposed and traced

during all thyroid surgeries. It has been realised that the RLN has extralaryngeal branching and this can be damaged if the individual branches are not taken care of by meticulous dissection.^{3,4} Exposure of EBSLN and individual ligation of superior thyroid artery branches in the medial thyroid space was initially stressed to avoid injury to it.^{5,6} Total thyroidectomy is indicated for differentiated thyroid carcinomas, toxic thyroid disease, multinodular goiter, and thyroiditis. An increasing proportion of thyroid operations are now done as total thyroidectomy.

Total thyroidectomy carries potential risk to all four parathyroid glands and both recurrent laryngeal nerves, transient hypocalcaemia and permanent hypoparathyroidism are well-known sequels of total thyroidectomy. Post-thyroidectomy hypocalcemia is a serious early complication. Patients must therefore be carefully observed in the postoperative period.

Estimates indicate that transient hypoparathyroidism prevalence rates range between 6.9% and 46% and permanent hypoparathyroidism rates vary from 0.4% to 3%.⁷ Hypocalcaemia occur secondarily to surgical trauma, devascularization, and unintentional removal of parathyroid glands. In this study we will analyze the surgical anatomy of the laryngeal nerves, both RLN and EBSLN. We will also look for the identification of parathyroid glands and their preservation.

Methods

The present study entitled "A Prospective study of Surgical Management of Thyroid swellings with special emphasis on Surgical Techniques for Preservation of Recurrent Laryngeal Nerve, External Branch of Superior Laryngeal Nerve and Parathyroid Glands" was conducted on the patients of thyroid swelling, who attended IPD of Otorhinolaryngology and Head and Neck Surgery Department, S.P. Medical College and associated

Hospitals Bikaner, Rajasthan from April 2016 to March 2017. The study protocol was reviewed and approved by the Ethics Committee of SP Medical College and Hospitals, Bikaner.

Inclusion criteria

1. All patients attended ENT OPD with complaints of solitary thyroid swelling willing for surgery.
2. Patients with diffuse thyroid swelling not responding to medical management.

Exclusion criteria

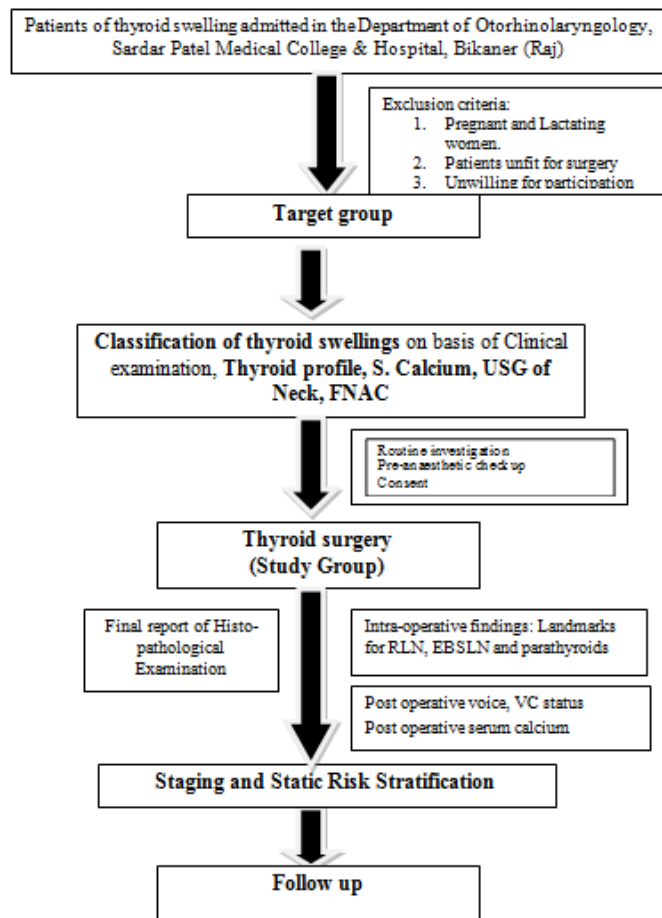
1. Patients with deranged thyroid function test.
2. Patients unfit/ unwilling for surgery.

A written fully explained consent stating the voluntary participation of subjects in the study was taken before the enrolment of the subjects.

Detailed history was taken as to age, sex, socioeconomic status, occupation, nature and duration of symptoms etc., including exposure of the neck to radiation during childhood or for cancer treatment, exposure to radiation fallout, and a family history of thyroid cancer, was obtained for all patients.

In addition, information about the rate of growth and presence of symptoms such as hoarseness, dysphagia, aspiration, and shortness of breath was obtained. Basic surgical steps included total dissection of the recurrent laryngeal nerve over its entire cervical course until they entered the larynx. Careful dissection done along the thyroid capsule to identify and preserve parathyroid glands with their vascular supply. Postoperatively patients were monitored for signs and symptoms of hypocalcaemia.

Flow Chart:



Results

In the presented study 60 cases of thyroid swelling who had undergone thyroid surgery in the Department of ENT were included. 56 patients were female and 4 were male. All the patients were euthyroid at the time of admission 6 cases were on thyroxine, in them 3 were on 100µgm and 3 patients on 50ugm. A total of 65 thyroid surgeries were performed during the study period in 60 study patients. The commonest age group of patients to be operated in this study group was 31-40 yrs. On preoperative evaluation, all cases had normal vocal cords and maximum number of patients 40% (22/60) presented in the age group of 31-40 years. The most common pathology observed in the thyroid gland for which surgery was indicated, according to preoperative FNAC report on Bethesda system of thyroid cytopathology, was benign

thyroid lesion 54 cases (90%) followed by 2 cases Follicular neoplasm or Suspicious for a follicular neoplasm, 2 cases of Suspicious for Malignancy (papillary carcinoma thyroid), one case of atypia / follicular lesion of undetermined significance and one case of malignancy cystic nodule. During our study period, totally 60 thyroid surgeries were done for various diseases of the thyroid. Solitary nodule of thyroid goiter was the commonest indication for surgery with 36 cases (60%), followed by 22 cases (36.66%) multinodular goiter and two cases of suspicion for Malignancy (3.33%) on radiological diagnosis bases. In our study post operative final histopathology Of the 48 cases reported colloid goiter, followed 7 cases Papillary Carcinoma, 3 cases with Hashimoto's Thyroiditis and 2 cases with follicular adenomas.

A total of 72 EBSLN and RLN were dissected. Type 1 nerve was the commonest among the 20 (47.61%) right-side EBSLN and 15 (50%) EBSLN on the left. Type 2A 7 (16.67%) cases right side and 6(20%) left side. Type 2B 2 (4.76%) cases right side and 1(3.33%) left side. 26.67% of the nerves on the left and 30.95% on the right side were not identified.

Discussion

Pressure symptoms were seen in 6.67% (4 cases) as against 29% in Antonio Rios *et al.* (2005) study.⁸ In our study 2 cases (3.33%) presented with difficulty in swallowing, 1 case (1.67%) with change in voice and 1 case (1.67%) with difficulty in breathing. Thus difficulty in swallowing was the commonest pressure symptom. Transient hypoparathyroidism was seen in 2 patients (3.33%) who were observed during the first post-operative week and all recovered completely with oral calcium and I.V. calcium therapy. There was no permanent hypoparathyroidism. T.A. Day *et al.*⁹ (2006) shows that there was 28% of temporary hypocalcemia and 0.9% with

permanent hypocalcemia. Temporary recurrent laryngeal nerve palsy was seen in 2 cases, which recovered within a month. There was no permanent recurrent laryngeal nerve palsy. Temporary RLN palsy was seen in 8%, permanent RLN palsy was seen in 0.9% in T. A. Day *et al.* (2003)⁸.

Description of the location of parathyroid glands based on surgical series poses some challenges. In the present series, we first identified inferior thyroid artery and then followed its branches to superior and inferior parathyroid area, then capsular dissection technique with use of bipolar cautery is followed to ensure the blood supply of parathyroid glands. Various landmarks have been described to identify the EBSLN in thyroid surgery. As described by Stell and Maran, the nerve lies in the Joll's triangle.¹⁰ The sternothyrolaryngeal triangle of Joll is formed laterally by the upper pole of the thyroid gland and the superior thyroid vessels, superiorly by the attachment of the strap muscles to the thyroid cartilage and medially by the midline. On its floor lies the cricothyroid muscle supplied by the EBSLN. In our dissection involving 67 RLN's majority had single branch (67.50% on the right side and 66.67% on the left); however, there were two or more branches in 22.50 % on the right side and 25.92 % on the left; . Casella *et al.*⁵ noticed that RLN had branches in 25.7% on the right side and 22.9% on the left. In our study non identification rate of RLN was 3.07%. The relationship of the RLN to the ITA can vary. In our patients 47.76 % is in between the branches of ITA, 23.88% passes deep to the ITA, and the remaining are superficial to the artery. There was no mortality in our series.

Limitations

We have not performed serum thyroglobulin, Anti-thyroid antibodies assessment and Thyroid scans due to non-availability of these investigations and financial constrains of the study population.

We were not having the facility of frozen section in our institute at the time of study so we could not detect the papillary carcinoma at the time of surgery. Therefore we have to do completion thyroidectomy in 5 cases of papillary carcinoma.

Conclusions

Sixty patients of thyroid swelling were evaluated with respect to age, sex, duration of swelling and were investigated with FNAC, and Radiological Diagnosis. Operated specimen subjected to histopathological examination and results were analyzed.

1. Solitary nodule / Colloid cyst / cystic degeneration and Multinodular goiter are the commonest thyroid disease in our hospital.
2. Thyroid swelling is more common in females (Female to male ratio 14:1) majority are in the age group of 21-40 years, 32 cases (53.3%)
3. The main indications of surgery in Multinodular goitre are cosmetic problem, pressure effect symptoms, secondary thyrotoxicosis and suspicion of malignancy.
4. The result of our study confirms that iatrogenic injury to the RLN, or its branches, can be avoided by seeking, identifying and exposing the nerve and by following its course carefully. Cases in which the RLN cannot be identified; intraparenchymal dissection or subtotal excision is preferable. It must be kept in mind that risk of iatrogenic RLN injury incidence is higher in reoperation cases and thyroid cancer cases, thus, these patients must be informed regarding this condition preoperatively.

References

1. Jatin P. Shah. Thyroid and Parathyroid gland. *Jatin Shah's Head and Neck Surgery and Oncology* 4th Edition Mosby pp. 471-525.
2. Bliss RD, Gauger PG, Delbridge LW. Surgeon's approach to the thyroid gland: surgical anatomy and the

importance of technique. *World Journal of Surgery*.2000;24(8):891–897.

3. Casella C, Pata G, Nascimbeni R, Mittempergher F, Salerni. Does extralaryngeal branching have an impact on the rate of postoperative transient or permanent recurrent laryngeal nerve palsy? *World J Surg*. 2009;33(2):261–265.

4. Lekacos NL, Tzardis PJ, Sfikakis PG, Patoulis SD, Restos SD. Course of the recurrent laryngeal nerve relative to the inferior thyroid artery and the suspensory ligament of Berry. *International Surgery*. 1992;77(4):287–288.

5. Cernea CR, Ferraz AR, Nishio S, Dutra A, Hojaj FC, dos Santos LRM. Surgical anatomy of the external branch of the superior laryngeal nerve. *Head and Neck*. 1992;14(5):380–383.

6. Yalacin B, Tubbs RS, Durmaz A et al. Branching pattern of the external branch of the superior laryngeal nerve and its clinical importance. *Clinical Anatomy*. 2012;25(1): 32–39.

7. Sakorafas GH, Stafyla V, Bramis C, Kotsifopoulos N, Kolettis T, Kassaras G. Incidental parathyroidectomy during thyroid surgery: an underappreciated complication of thyroidectomy. *World J Surg*. 2005;29(12):1539-43.

8. Ríos A, Rodríguez JM, Canteras M et al , Galindo PJ, Tebar FJ, Parrilla P Surgical Management of Multinodular Goiter With Compression Symptoms. *Arch Surg*. 2005;140:49-53.

9. Day TA, Davis BK. Oral cancer treatment. *Curr Treat Options Oncol*. 2003 Feb;4(1):27-41.

10. Rossi P, Tracht DG, Ruzicka FF. Thyroid angiography—Techniques, anatomy and indications. *Br J Radiol*.1971;44:911–926.

Table 1:- Study population and epidemiology of study patients with thyroid swelling.

Table 2:- Clinical presentation of study patients with thyroid swelling

Total number of patients enrolled	60	
Final HPE		
Benign thyroid disease	53	88.33
Papillary Carcinoma	7	11.67
Total number of surgeries	65	
Total thyroidectomy	7	10.76
Hemi thyroidectomy	53	81.53
Completion thyroidectomy	5	7.69
Male	4	6.67
Female	56	93.33
Total No. of cases	Number of	Percentage
Presenting complaints		
Swelling	60	100
Pain	7	11.66
Recent increase in size	3	5
Alteration in voice	1	1.66
Difficulty in	2	3.33
Difficulty in breathing	1	1.66
Toxic symptoms	0	0
Size of swelling cases (cm)		
≤2	13	21.66
2-4	44	73.33
>4	3	5
Duration of swelling		
1-6 months	26	43.33%
6-12 months	11	18.33
1-2 years	9	15
>2 years	14	23.33
Site and Side and Concerned Lobe		
Right lobe	33	55

Left lobe	20	33.33
Diffuse swelling	7	11.66
Progression of swelling		
Gradual	51	85
Rapid	03	5
Stationary	06	10

Table 3: Locations of inferior parathyroid glands.

Locations	Right n=23	Left n=13
At or just caudal to Tubercle of Zuckerkandl	9	6
Deeply located on lateral surface of thyroid	2	1
Superficially located on lateral surface of thyroid	9	5
Deeply located, away from lower lateral surface of thyroid	3	1

Table 4: Locations of superior parathyroid glands.

Locations	Right n=38	Left n=27
Low down on deep surface of thyroid, medial to RLN (not seen from above during mobilization of upper pole)	22	17
At or just cranial to Tubercle of Zuckerkandl	9	6
Deep surface of thyroid (seen from above during mobilization of upper pole)	7	4

Fig. 1: Showing RLN branching pattern (right versus left side).

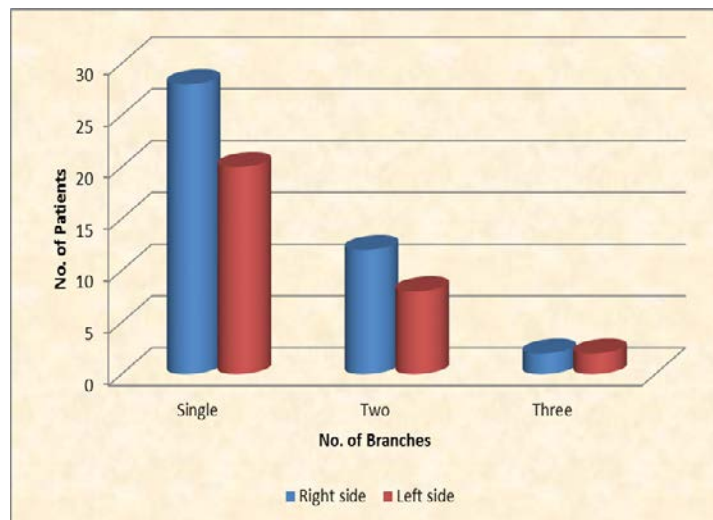


Fig. 2- Showing relationship between the recurrent laryngeal nerve (RLN) and the inferior thyroid artery (ITA), considering the side of the neck.

