



## **CBCT Evaluation of the Shaping Characteristics of Hyflex EDM, VTAPER 2H and Twisted Files In The Mesial Canals Of Mandibular First Molars –An In Vitro Study**

<sup>1</sup>Dr Annil Dhingra, Prof and Head, Department of Conservative Dentistry and Endodontics, Seema Dental College and Hospital Rishikesh, Uttarakhand, India

<sup>2</sup>Dr Nitika, Post Graduate Student, Department of Conservative Dentistry And Endodontics, Seema Dental College And Hospital Rishikesh, Uttarakhand, India

<sup>3</sup>Dr Marisha Bhandari, Reader, Department Of Conservative Dentistry and Endodontics, Seema Dental College and Hospital Rishikesh, Uttarakhand, India

<sup>4</sup>Dr Sheetal Grover, Senior Lecturer, Department of Conservative Dentistry And Endodontics, Seema Dental College And Hospital Rishikesh, Uttarakhand, India

<sup>5</sup>Dr Pulkit Gupta, Senior Lecturer, Department of Conservative Dentistry And Endodontics, Seema Dental College And Hospital Rishikesh, Uttarakhand, India

<sup>6</sup>Dr Sumit Sabharwal, Senior Lecture, Department Of Conservative Dentistry & Endodontics, Seema Dental College & Hospital, Rishikesh, Uttarakhand, India

**Correspondence Author:** Dr Annil Dhingra, Prof and Head, Department of Conservative Dentistry and Endodontics, Seema Dental College and Hospital Rishikesh, Uttarakhand, India

**Type of publication:** Original Research Paper

**Conflicts of Interest:** Nil

### **Abstract**

The main aim of root canal treatment is proper cleaning and shaping of the root canal system. The root canal instrumentation needs to preserve the existing root anatomy, the position of the apical foramen and the original curvature this is possible only when there is continuous tapering of the root canal which helps the irrigating solution to flow easily within canal to remove debris and for the proper placement of the obturating material. Considerable importance should be given not to cut excessive dentin to get adequate taper of the canal. So, the challenge for every file system is to clean and shape the root canal without cutting the excessive dentin. Preparation of root canal system includes both enlargement and shaping of the complex endodontic space together with its disinfection. To fulfill these requirements

a variety of manual, rotary, and reciprocating instruments have been developed.<sup>1</sup>

The introduction of nickel-titanium (NiTi) instruments allowed a safer and easier preparation of root canals with complex anatomic characteristics. However, during preparation, especially when preparing curved canals, iatrogenic errors, such as ledges, zips, perforations, and root canal transportation, can occur. Therefore, coronal enlargement and the prior creation of glide paths have been shown to minimize procedural errors during root canal treatment.<sup>6,16</sup>

Technological advancements in rotary nickel-titanium (NiTi) instruments have led to new design concepts and easier and faster techniques that preserve the original canal shape with considerably less iatrogenic error

HyFlex rotary instruments (Coltene-Whaledent, Allstetten, Switzerland) have been introduced. They are made from a controlled memory NiTi wire, which is manufactured by a unique process that controls the material's memory. This EDM feature makes the files extremely flexible and makes the instruments more resistant to cyclic fatigue than non-EDM NiTi instruments. The HyFlex instrument has a symmetric cross-sectional design with 3 cutting edges. Unlike other instruments, deformed HyFlex instruments are able to regain their original shape after a sterilization procedure. These NiTi files are manufactured by an innovative method that gives control over the material's memory.

Twisted file (SybronEndo, Orange, CA, USA) is manufactured by twisting a NiTi wire with a triangular cross-section and R-phase crystalline structures created by heating and cooling. After completion of twisting, the file is heated and cooled again to maintain its new shape while converting back into its austenite crystalline structure. It is another novel file that uses a combination of continuous rotation and reciprocating motion. The file uses continuous rotation when it is exposed to minimal or no applied load and uses reciprocal motion when it engages dentin and a load is applied. Manufacturers have claimed that this adaptive technology and twisted file design using R-phase treatment increase debris removal and flexibility and allow the file to adjust to intracanal torsional forces depending on the amount of pressure placed on the file.

V Taper 2H (SS White Dental Inc., Lakewood, NJ, USA) were only recently released. VTaper 2H variable taper Ni-Ti rotary files feature a parabolic cross-section design that combines high efficiency and flexibility while being safe and resistant to fracture. These files provide better access for irrigation and cleaning, and three dimensional obturation by providing a deep apical shape.

## **Aims and Objective**

**AIM:** The aim of this study was to evaluate the canal modifications in curved canals following cleaning and shaping of the root canal using various file systems.

## **Objectives**

The objective of the study were

- To Evaluate and Compare the Canal Transportation and Canal Volume Increase after Cleaning And Shaping with Protaper Next (Dentsply Maillefer, Ballaigues, Switzerland)
- To Evaluate and Compare the Canal Transportation and Canal Volume Increase after Cleaning and Shaping with Hyflex EDM (Coltene, Altstatten, Switzerland)
- To Evaluate and Compare the Canal Transportation and Canal Volume Increase after Cleaning and Shaping with NeoNITI files (Orikam, Germany).

## **Material and Method**

Sixty freshly extracted permanent mandibular first molars were cleaned of adherent tissue tags and hard deposits using ultrasonic scalers. The teeth were stored in 0.9% sodium chloride containing 0.2% sodium azide solution for preventing bacterial growth in an incubator at 37°C until used.

Pre-operative working lengths were taken.

All teeth were decoronated with a diamond disk at the level of 14 +\_mm from the apex perpendicular to the long axis of the root to obtain a relatively standard tooth length. The pulpal remnants were extirpated using a broach. Apical gauging was carried out using size 10, 15 and 20 K-Files. Only the teeth in which size 10 K-File could barely see through the apex and size 15 K-File that snugly fits at the working length were included in the study. The working length was established 1mm shorter than the length at which a size 10 K-File was visualized at the

apical foramen when observed under microscope at 25X magnification.

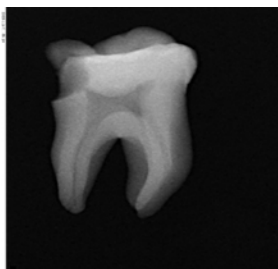

Figure 1: samples pre-Operative Radiograph

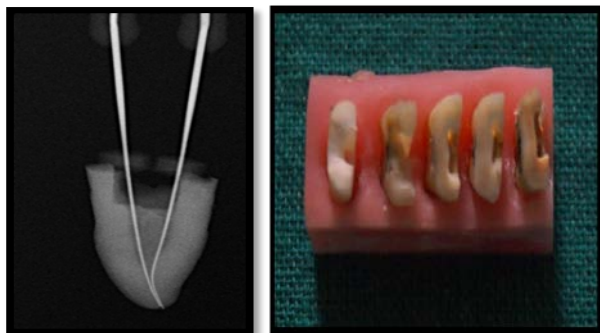


Figure 2 and 3: working Length Radiograph Samples in acrylic Mount

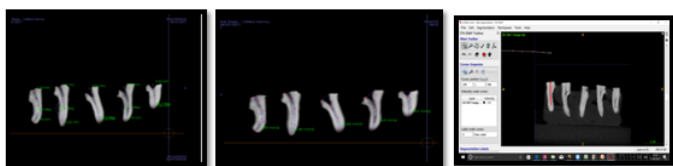


Figure 4: Measuring Canal Curvature ,Area and Volume

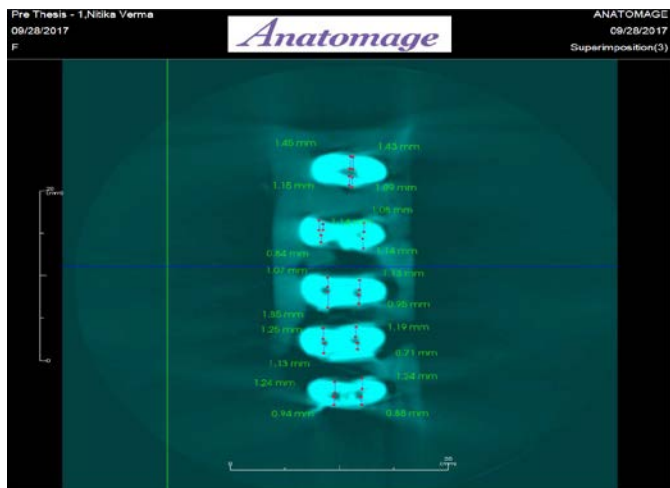


Figure 5: Superimposition Images

Inclusion criteria stipulated that the tooth had a curved mesial root with two separate canal and apices, with curvature angles ranging within 20-40° (Schneider, 1971).

Standardized radiographs were taken in a buccolingual and mesiodistal dimension before the instrumentation. The specimens were placed in a radiographic mount .The radiographs in the buccal-lingual dimension were taken to confirm the presence of two distinct and separate root canals . In the mesiodistal dimension K-File no.10 were inserted into the buccal and lingual canals to assess the degree of root canal curvature according to Schneider’s technique. Coronal access was achieved by using Endo-Access & Endo-Z burs to obtain a straight line access. Each tooth was sectioned through the furcation and mesial portion of the root and crown was used. Distal roots with the respective part of crown were sectioned at the furcation level and discarded. All mesial portion root canal were controlled for apical patency with a K-File No.10. Periapical radiographs were recorded to confirm the working length.

Teeth were imaged (90 micron resolution) with cone beam computed tomographic imaging software CS9300 equipment(Carestream Healthcare India(P) Ltd ) set at 84Kv,5mA,10.8 second exposure and a slice thickness of 76 um to obtain a pretreatment outline of the root canals. Scanning was performed through. The acquired images were reconstructed into cross sectional slices using standardized parameters for beam hardening and similar contrast limits. The volume of interest was selected extending from the furcation level to the apex of the root, resulting in the acquisition of 700-900 transverse cross section and dentin thickness from the level of the furcation to the apex of the root were recorded. All the scans will be reoriented with respect to x, y, z axis. The canal transportation and volume of root canals will be evaluated at 1.0, 2.0, 3.0, 4.0 and 5.0 mm interval .Study images will be reconstructed from the volumetric data set in planes perpendicular to the selected tooth axis.

Cleaning and shaping was done with crown down technique using the file rotary file systems in different groups with EDTA gel as lubricant. Apical patency was confirmed by inserting a size 10 K-File. Through the apical foramen during and after the root canal preparation. The canals were constantly irrigated with 2ml of 5% NaOCl solution using a 30 gauge side port opening needle after use of every instrument .after finishing the instrumentation, the prepared canals were rinsed with 10 ml of 17% EDTA solution followed by a final flush with 10 ml of sterile saline to remove the smear layer and any traces of NaOCl.

**Group 1: Pro Taper Next files**

Cleaning and shaping of the canals were done by using this file system in the endodontic rotary system at the torque and speed provided by the manufactures and it was rinsed thoroughly.

**Group 2: Hyflex EDM files**

The procedure was followed and done as per the manufacturer’s instructions.

**Group 3: Neo NITI files** The procedure was followed and done as per the manufacturer’s instructions. The teeth were then marked on the sides to differentiate the mesial and buccal sides; they were mounted on the acrylic block upto five in a block. Block was also marked to differentiate the front and back side of the block. The marked block with the teeth was placed into the CBCT for scanning Canal modification were calculated pre and post the scans.Comparisons parameters were calculated by subtracting values obtain for treated canals with those from untreated canals through CBCT

**Result**

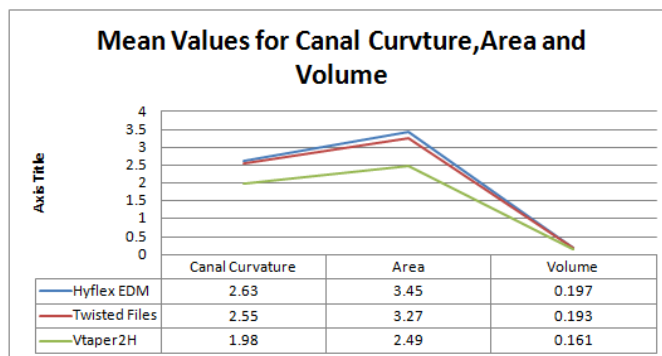
The mean difference in Curvature Angle,Area and Volume from pre to post treatment was done between Protaper, Hyflex EDM and Neo NITI using the One-ANOVA test with post-hoc bonferroni test for inter-group

comparisons. The mean difference in Curvature Angle,Area and Volume are from pre to post treatment was significantly more among Hyflex EDM in comparison to Neo NITI which was significantly more than Protaper.

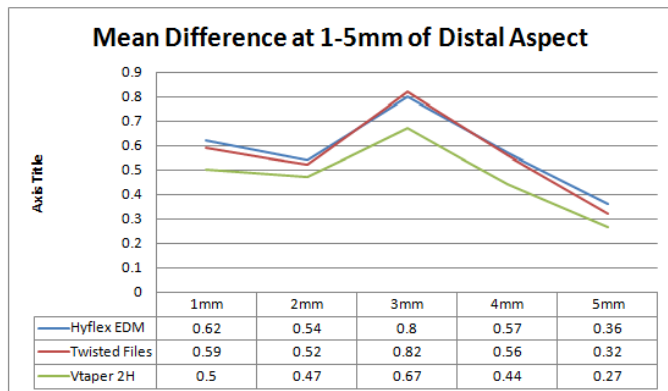
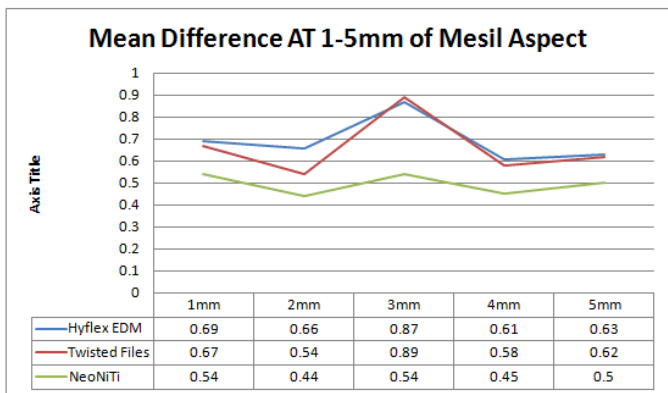
The comparison of mean value from 1mm to 5mm in Mesial aspect was done between pre and post treatment using the Paired t-test. The mean of 1 to 5mm of Mesial increased significantly from pre to post treatment among Protaper, Hyflex EDM and Neo NITI groups. The comparison of mean value at 1mm to 5mm in Distal aspect was done between pre and post treatment using the Paired t-test. The mean 1 to 5mm of Distal increased significantly from pre to post treatment among Protaper, Hyflex EDM and Neo NITI groups.

Difference in CURVATURE ANGLE from post to pre treatment					
	Mean	Std. Deviation	F-value	p-value <sup>a</sup>	Post-hoc comparisons <sup>b</sup>
Hyflex EDM	2.63	0.83	5.308	0.007*	1 > 2 > 3
Twisted files	2.55	5.70			
Vtaper2h	1.98	4.46			
Difference in Area from post to pre treatment					
	Mean	Std. Deviation	F-value	p-value <sup>a</sup>	Post-hoc comparisons <sup>b</sup>
Hyflex EDM	3.45	1.06	14.312	0.001*	1 > 2 > 3
Twisted files	3.27	0.44			
Vtaper2h	2.49	0.81			
Difference in Volume from post to pre treatment					
	Mean	Std. Deviation	F-value	p-value <sup>a</sup>	Post-hoc comparisons <sup>b</sup>
Hyflex EDM	0.197	0.091	4.285	0.003*	1 > 2 > 3
Twisted files	0.193	0.096			
Vtaper2h	0.161	0.063			

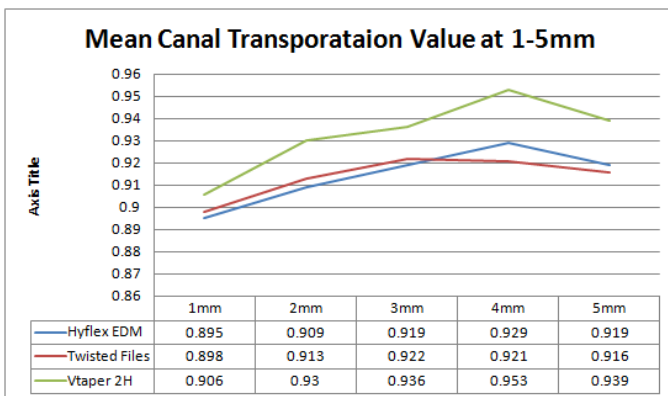
Table 1: Mean Vlaue Of Canal Curvature,Area And Volume.



Graph 1: Mean Values of Curvature Angle, Area, Volume



Graph 2 & 3: mean difference at 1-5mm in mesial and Distal aspect.



Graph 4: Mean canal transportation from 1-5mm

### Discussion

The main goal of root canal preparation is to clean the root canal system while maintaining the original shape of the canal(s). Achieving this goal can facilitate effective irrigation, root canal medication, and finally, the three dimensional obturation. It also aims to shape and clean the root canal system effectively while maintaining the original configuration of the canal (Peters and Peters

2011). Continuous tapered preparation with increasing diameter from the canal orifice to the apex is desired for the effective irrigation and a three dimensional obturation of the root canal space (Walton 1976)<sup>13</sup>

ProTaper Next (Dentsply Maillefer, Ballaigues, Switzerland) (PTN) has recently been introduced by Dentsply Maillefer. The system consists of X1, X2, X3, X4 and X5 file. These files have yellow, red, blue, double black, and double yellow identification rings on their handles. The instrument is available in various sizes (21mm, 25mm and 31mm). The system has a rectangular cross section with only two edges in contact with the canal wall at one time producing the characteristic asymmetric motion thus maintaining the anatomy of the canal. This feature makes PTN better than ProTaper Universal (Dentsply Maillefer, Ballaigues, Switzerland) (PTU) as PTU has a triangular cross section with all the three edges contacting the canal walls at the same time.

Canal curvature is the main risk factor for instrument failure because of flexural stresses and cyclic fatigue (Peters 2004, Hulsmann 2005, Peters and Peters 2011). To reduce these stresses, PTN rotary design combines multiple progressive tapers along with the M wire technology thus, adequately maintaining the original canal curvature (Yun and Kim 2003, Unal *et al.* 2009). The shaft size of PTN is 13 mm as compared to PTU that is 15 mm. This makes posterior teeth better accessed by PTN as compared to PTU. As till date no study has been done to evaluate this new file system, various parameters have been studied to evaluate canal shaping using PTN in this study.<sup>12</sup>

Neoniti A1 (NEOLIX, Chatres-la-Forêt, France) is one of the single-file systems with full rotary motion. This system has continuous rotating movement and is made up of special alloy that permits the file flexibility. This system is produced with three different sizes (20/0.08,

25/0.08 and 40/0.08) that are recommended to be used with speed of 300 to 500 rpm and torque limit of 1.5 N/cm. According to its manufacturer, the wire-cut electric discharge machining mechanism allows a sharper edge as well as much greater flexibility. This system is applied with a single-length preparation procedure that allows canal preparation at working length with a disposable single file. If proved efficient and safe, such simplified single-file instrumentation systems are favorable because of their ease of use. However, this system is not assessed yet except in a recent study, and this allegation should be proved by further investigation<sup>4,5,6</sup>

Recently, HyFlex rotary instruments (Coltene-Whaledent, Allstetten, Switzerland) have been introduced. This EDM feature makes the files extremely flexible and makes the instruments more resistant to cyclic fatigue than non-EDM NiTi instruments. The HyFlex instrument has a symmetric cross-sectional design with 3 cutting edges. Unlike other instruments, deformed HyFlex instruments are able to regain their original shape after a sterilization procedure.<sup>11</sup> Surface and microstructural characterization of EDM prototypes revealed the typical spark-machined surface of a NiTi EDM alloy. No fractures were registered during root canal instrumentation. No evident surface alterations and minor degradation were observed between new and used instruments. The metallographic analysis of new and used files disclosed a homogeneous structure, mostly composed of lenticular martensite grains, and some residual austenite. The cyclic fatigue test showed an increase of fatigue resistance up to 700% on the EDM compared to CM files<sup>3</sup>

This study evaluated the canal shaping characteristics of the Hyflex EDM, Twisted files, Vtaper2H, NeoNiTi Files and Pro Taper Next using CBCT imaging, a nondestructive, reproducible, and well-established method

for the 3D assessment of the root canal preparation. All instruments showed untouched areas of the root canal wall, indicating that none were able to completely clean the dentin walls, which is in agreement with previous studies on NiTi rotary systems however, it deserves attention that the mean range of the untouched areas of the root canal wall<sup>8</sup>

It has been shown that variations in canal geometry before instrumentation may have a greater effect on observed changes than the instrumentation techniques themselves. In this way, a less complex preoperative configuration of the root canals selected in this study may explain the results. Overall, the Hyflex EDM systems resulted in significantly less untouched canal walls and a higher increase in the surface area, perimeter, and minor diameter of the canals than the V NeoNiTi Files and ProTaper Next system. These results might be explained by differences in the design of the instruments.

In the current study, movements of the centers of gravity were metrically evaluated in absolute numbers (mm), slice by slice, as canal transportation. Overall, Hyflex EDM produced significantly less canal transportation than ProTaper Next and NeoNiTi instruments, they are manufactured from different alloys and the more flexible alloy of the Hyflex EDM, enhanced through a proprietary heat treatment technology, imparts a reduced restoring force and may explain why these instruments remained more centered in the canal than ProTaper Next and NeoNiTi Files during use.

Apical transportation is difficult to measure because no gold standard exists for this measurement; also, various methods with different limitations are noted in this regard. The presently used methods are comprised of radiographic imaging, cross-sectioning, and longitudinal cleavage of the samples. In recent years, cone beam computed tomography (CBCT) has been added as a measuring

device for this purpose with acceptable results because of its nondestructive nature and the possibility to have precise linear measurements.

The comparison of mean canal transportation at different levels( 1mm,2mm,3mm,4mm and 5mm respectively) was done using One ANOVA test with post-hoc Bonferroni test for inter group comparisons. The mean canal transportation was significantly more among Protaper in comparison to Neo NITI which was significantly more than Hyflex EDM

However more in-vitro studies need to be conducted to correlate the results of this study.

### **Conclusion**

Objective in root canal preparation is to develop a shape that tapers from apical to coronal, maintaining the original canal shape. With advent of Instruments manufactured from nickel titanium alloys (NiTi), there was significant improvement of quality of root canal shaping, with predictable results and less iatrogenic damage, even in severely curved canals

The aim of this study was to evaluate the canal modifications in curved canals following cleaning and shaping of the root canal using various file systems (ProTaper Next, Hyflex EDM Files, NeoNiTi Files) canals with those from untreated canals through CBCT. The results of this in-vitro study regardless of the instrument used to perform cleaning and shaping, the cross-sectional area increased at all levels. In this study Hyflex EDM Files resulted in less transportation as compared to other groups. Within the parameters of this study it was concluded that Hyflex EDM Files did the least modifications in canal anatomy as compared to other groups. Whereas ProTaper Next Files did maximum modifications in canal anatomy in curved canals.

### **References**

- [1]. Amr M.Elnaghy, Shaymaa E.Elsaka Evaluation of Root Canal Transportation, Centering Ratio, and Remaining Dentin Thickness Associated with ProTaper Next Instruments with and without Glide Path Journal of Endodontics Volume 40, Issue 12, December 2014, Pages 2053-2056
- [2]. Kiamars Honardar, Hadi Assadian, Shahriar Shahab et al Cone-beam Computed Tomographic Assessment of Canal Centering Ability and Transportation after Preparation with Twisted File and Bio RaCe Instrumentation Journal of Dentistry, Tehran University of Medical Sciences, Tehran, Iran (2014; Vol. 11, No. 4)
- [3]. A. Dhingra, S. Banerjee, V. Yadava, N. Aggarwala Canal Shaping with ProTaper Next and ProTaper Universal: A Comparative Study Annals of Dental Research, Volume 4, Issue 1, 2014
- [4]. A. M. Elnaghy Cyclic fatigue resistance of ProTaper Next nickel-titanium rotary files Int Endod J 2014 Nov;47(11):1034-9.
- [5]. Anshul Arora, Sonali Taneja, and Mohit Kumar Comparative evaluation of shaping ability of different rotary NiTi instruments in curved canals using CBCT JCD 2014 17(1) 35-39.
- [6]. Anil Dhingra, Nayasha Manchanda Modifications in Canal Anatomy of Curved Canals of Mandibular First Molars by two Glide Path Instruments using Cbct Journal of Clinical and Diagnostic Research. 2014 Nov, Vol-8(11): ZC13-ZC17.
- [7]. Khaly Bane, Babacar Faye, Mouhamed Sarr, Seydina O Niang, Diouma Ndiaye, Pierre Machtou Root Canal Shaping by Single-File Systems and Rotary Instruments: a Laboratory Study IEJ Iranian Endodontic Journal 2015;10(2): 135-139.
- [8]. Ertuğrul Karataş, Hicran Ateş Gündüz, Damla Özsu Kırıcı, Hakan Arslan, Meltem Çolak Topçu, Kübra

Yeşildal Yeter Dentinal Crack Formation during Root Canal Preparations by the Twisted File Adaptive, ProTaper Next, ProTaper Universal, and WaveOne Instruments Journal of Endodontics vol 41,issue 2,feb 2015(261-264)

[9]. Gurram Samuel Simpsy, Girija S Sajjan, Padmaja Mudunuri, Jyothi Chittam, Nalam N. V. D. Prasanthi, Pankaj Balaga Shaping ability of reciprocating motion of WaveOne and HyFlex in moderate to severe curved canals: A comparative study with cone beam computed tomography J Conserv Dent. 2016 Nov-Dec; 19(6): 578–582.

[10]. Fariborz Moazzami , Leila Khojastepour , Mohammadreza Nabavizadeh , Mina Seied Habashi Cone-Beam Computed Tomography Assessment of Root Canal Transportation by Neoniti and Reciproc Single-File Systems Iranian Endodontic Journal 2016;11(2): 96-100

[11]. Shruti Jayaprakash Shah., Anamika C. Borkar and Vishwajit B Apical Extrusion Of Debris And Irrigant Using Neolix And One-Shape Rotary Systems: A Comparative Study International Journal of Recent Scientific Research Research Vol. 7, Issue, 5, pp. 11325-11327, May, 2016

[12]. Aminsobhani M, Khalatbari MS, Meraji N, Ghorbanzadeh A, Sadri E.Evaluation of the Fractured Surface of Five Endodontic Rotary Instruments: A Metallurgical Study.Iran Endod J. 2016 Fall;11(4):286-292.

[13]. Yu Gu , Kee-Yeon Kum , Hiran Perinpanayagam Various heat-treated nickel-titanium rotary instruments evaluated in S-shaped simulated resin canals Journal of Dental Sciences (2017) 12, 14e20

[14]. Mustafa Gündoğar, DDS, PhD Correspondence information about the author DDS, PhD Mustafa Gündoğar Email the author DDS, PhD Mustafa Gündoğar Cyclic Fatigue Resistance of OneShape, HyFlex EDM,

WaveOne Gold, and Reciproc Blue Nickel-titanium Instruments J Endod. 2017 Jul;43(7):1192-1196  
[15]. Pedullà E, Genovesi F, Rapisarda S, La Rosa GR, Grande NM, Plotino G, Adorno CG Effects of 6 Single-File Systems on Dentinal Crack Formation.J Endod. 2017 Mar;43(3):456-461